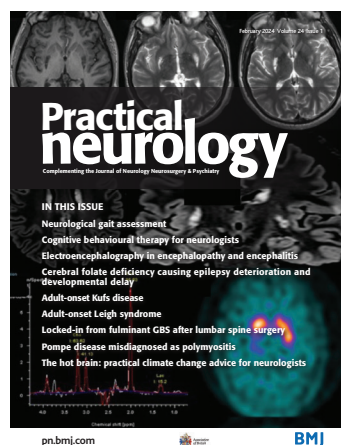


Cover image: MR scan of brain with (A) axial 3D T1-weighted, (B+C) T2 turbo spin echo (TSE) and (D+E) axial and coronal 3D T2 fluid-attenuated inversion recovery (FLAIR) sequences showing progressive bilateral basal ganglia abnormalities with the addition of symmetrical abnormal signal surrounding the posterior body of lateral ventricles, and also cortical and subcortical involvement. (F) MRI spectroscopy (MRS), voxel placed over normal appearing white matter in the anterior right centrum semiovale. MRS performed at a long echo-time (TE) of 270 ms. A characteristic lactate double peak can be seen resonating at 1.3 ppm (G) abnormal FP-CIT single-photon emission computed tomography (SPECT) scan showing bilateral reduced uptake (see Watson-Fargie T, *et al.* page 49).

Highlights from this issue

- 1 Editors' commentary
P E M Smith, G N Fuller

Reviews

- 2  Electroencephalography in encephalopathy and encephalitis
H Morris, P W Kaplan, N Kane
- 11 Neurological gait assessment
S Mermelstein, P Barbosa, D Kaski

How to understand it

- 22 Cognitive behavioural therapy for neurologists
B Stanton, T Chalder, C Carvalho

How to do it

- 28 Hot brain: practical climate change advice for neurologists
S M Sisodiya

Neurological rarities

- 37 Fatal cerebral air embolism from atrio-oesophageal fistula following cardiac ablation
R Y S Keh, D du Plessis, G M Potter, C Kobylecki, P Cooper
- 41 Adult-onset Kufs disease
A Kelly, J Dunne, C Orr, N Lawn

A difficult case

- 45 Leigh syndrome: an adult presentation of a paediatric disease
T Watson-Fargie, V Marshall, N E Fullerton, V Leach, D Pilz, C V Y Hemingbrough, S Hopton, R W Taylor, Y S Ng, A Schaefer, G S Gorman, M E Farrugia
- 51 Posterior semicircular canal cupulolithiasis during acute pontomedullary demyelination
S Matos, A I Martins, A Jorge, M d C Macário, D Pereira, M Strupp, J Lemos

- 56 Cerebral folate deficiency: a treatable cause of late deterioration in epilepsy with developmental delay
F A Chowdhury, E Sokolov, J Anderson, D J Josifova, L Nashef

- 60 Non-convulsive status epilepticus associated with Whipple's disease
E Diab, M Aubignat, R Sarba, S Wannepain, O Godefroy, I Masmoudi

- 63 Locked in from fulminant GBS after lumbar spine surgery
R M Hass, E F M Wijdicks

- 66 Pompe disease misdiagnosed as polymyositis
A E Camelo-Filho, M R A Martins, J L d B de Souza, R B Maurício, P R Nóbrega

Test yourself

- 70 An unusual mimic of intracranial hypertension
N Ghane, J C Kattah, B Mannett, S H Hong

Image of the moment

- 74 Neurological presentation of profound hypothyroidism
C Paisey, G Chohan
- 76 Calvarial disease in secondary syphilis presenting as headache
J Garnham, G Dawe, M Bracchi, N Davies
- 78 Progressive multifocal leukoencephalopathy with hypointense halo on MRI
V L Braga, F P Sarmento, P Fraiman, D B Bichuetti, H B Ferraz, E M L de Oliveira

- 80 MRI changes in chronic crystal methamphetamine abuse
HMMTB Herath, N G Lutchman, M Jeffries, M Saleh, L Naidu, S Wimalaratna



This article has been chosen by the Editor to be of special interest or importance and is freely available online.



This article has been made freely available online under the BMJ Journals open access scheme. See <http://authors.bmj.com/open-access/>



This journal is a member of and subscribes to the principles of the Committee on Publication Ethics

www.publicationethics.org



When you have finished with this magazine please recycle it.

- 82** Primary position upbeat nystagmus
in thiamine deficiency
D A Pedrosa, R de Araújo Gleizer,
R C V Gomes, J M V de Albuquerque Filho,
B A Matos, R A Alquéres

Book club

- 84** *Empire of pain* by Patrick Radden Keefe
A-W Mahmood, T A T Hughes

Carphology

- 86** Carphology
A F Ben

ABN News

- 87** ABN news
M McCourt, L Kinton