




OPEN ACCESS

Spontaneous intracranial hypotension

Sanjay Cheema,^{1,2} Dwij Mehta,^{1,2} Ayman Qureshi,³ Parag Sayal,⁴ Salwa Kamourieh,² Indran Davagnanam,^{3,1} Manjit Matharu ^{1,2}

¹Department of Brain Repair and Rehabilitation, UCL Queen Square Institute of Neurology, London, UK

²Headache and Facial Pain Group, National Hospital for Neurology and Neurosurgery, London, UK

³Lysholm Department of Neuroradiology, National Hospital for Neurology and Neurosurgery, London, UK

⁴Victor Horsley Department of Neurosurgery, National Hospital for Neurology and Neurosurgery, London, UK

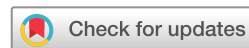Correspondence to

Dr Manjit Matharu, Department of Brain Repair and Rehabilitation, UCL Queen Square Institute of Neurology, London, WC1N 3BG, UK; manjit.matharu@nhs.net

Accepted 22 November 2023
Published Online First
22 December 2023



Listen to Podcast
pn.bmj.com



© Author(s) (or their employer(s)) 2024. Re-use permitted under CC BY-NC. No commercial re-use. See rights and permissions. Published by BMJ.

To cite: Cheema S, Mehta D, Qureshi A, et al. *Pract Neurol* 2024;**24**:98–105.

ABSTRACT

Spontaneous intracranial hypotension (SIH) is a highly disabling but treatable secondary cause of headache. Recent progress in neuroradiological techniques has catalysed understanding of its pathophysiological basis and clinical diagnosis, and facilitated the development of more effective investigation and treatment methods. A UK-based specialist interest group recently produced the first multidisciplinary consensus guideline for the diagnosis and treatment of SIH. Here, we summarise a practical approach to its clinical and radiological diagnosis, symptomatic and non-targeted interventional treatment, radiological identification of leak site and targeted treatment of the leak once it has been localised.

INTRODUCTION

Spontaneous intracranial hypotension (SIH) is a clinical and radiological syndrome caused by spinal leakage of cerebrospinal fluid (CSF) due to a dural tear, leaking meningeal diverticulum or CSF venous fistula. Its estimated incidence in the USA is 3.8 per 100 000 population per year,^{1,2} which translates approximately to 2500 new cases of SIH per year in the UK.

Patients with SIH can present to various healthcare settings including to general practice (GP) or neurology clinics with chronic daily headache, or to emergency department with complications such as subdural haematoma or cerebral venous sinus thrombosis. SIH is almost always treatable, but its optimal management requires coordinated multidisciplinary care between multiple clinical specialities.

A survey of patients with SIH in the UK showed that diagnostic delay and misdiagnosis are common.³ Patients presented to their GP a median of three times before being referred to a neurologist. In 45% of patients, the first neurologist they saw did not make the diagnosis, and the median time from symptom onset to diagnosis was 2 months. Investigations and treatments are also often delayed, meaning that only one-third of patients received

treatment within 12 weeks of seeing a neurologist.³ A survey of UK healthcare professionals identified a lack of awareness of SIH among non-specialists, variability in management pathways and difficulty accessing investigations such as myelography and treatments such as epidural blood patches.⁴

Guidelines for the diagnosis and management of SIH have recently been published by a multidisciplinary group of neurologists, neuroradiologists, neurosurgeons, anaesthetists and patient representatives,⁵ with input from international experts and UK-based professional bodies. The guideline addresses the most important steps in the patient pathway, including clinical diagnosis, radiological diagnosis, identification of the spinal CSF leak site, non-targeted and targeted treatment, symptomatic management, management of complications and follow-up.

This article summarises a practical approach to the diagnosis and treatment of SIH, based on the recommendations in the guideline.

Clinical diagnosis

SIH most commonly presents with orthostatic headache (ie, headache that begins or significantly worsens on becoming upright and improves soon after lying flat). Orthostatic headache occurs in approximately 92% of cases of SIH.⁶ The time of headache onset on becoming upright can be anywhere from immediate to many hours later ('second-half-of-the-day headache'),^{7,8} but the timing is usually consistent for any one patient. The headache usually improves within 30 min of lying flat. A minority of patients with radiological findings of SIH have either a non-orthostatic headache (5%) or no headache (3%).⁶ The orthostatic quality of the headache can attenuate over time,⁹ and therefore if seeing a patient months or years after the headache onset, it is important to enquire retrospectively about the headache quality soon after

Table 1 Symptoms of SIH

Symptom	Proportion*
Headache	97%
▶ Orthostatic	92%
▶ Non-orthostatic	8%
▶ Occipital	33%
▶ Diffuse/holocranial	30%
▶ Frontal	21%
▶ Frontal and occipital	11%
▶ Temporal	8%
Nausea/vomiting	54%
Neck pain/stiffness	43%
Hearing disturbance	28%
Dizziness	27%
Tinnitus	20%
Vertigo	17%
Reduced level of consciousness†	15%
Back pain	14%
Photophobia	11%
Movement disorders‡	10%
Cognitive symptoms	6%
Diplopia	6%

*Pooled estimates of proportions adapted from meta-analysis by D'Antona *et al.*⁶
†Likely over-represented by published reports of highly disabled patients.
‡Including gait disorders, ataxia, tremor, bradykinesia or poor balance.
§Most commonly non-specific concentration or word-finding difficulties.
SIH, spontaneous intracranial hypotension.

onset. Sometimes, SIH can begin with a thunderclap headache.¹⁰

SIH may lead to a large number of other symptoms, including vertigo, muffled hearing, hypoacusis, tinnitus, nausea/vomiting, photophobia, posterior neck pain, fatigue and cognitive impairment (commonly non-specific concentration difficulties, but rarely a behavioural variant frontotemporal dementia-like syndrome due to brain sagging) (see [table 1](#)).^{6,11} Rarely, SIH may present for the first time with a complication such as subdural haematoma, superficial siderosis or venous sinus thrombosis.^{11,12}

Orthostatic headache has several differential diagnoses (see [table 2](#)). Post-dural puncture headache and headache following post-surgical or post-traumatic spinal CSF leak give similar symptoms; however, in these situations, the site of intervention, and therefore site of spinal CSF leak, is known, unlike SIH, where the site of spinal CSF leak is unknown at the time of initial presentation. Therefore, in a patient with suspected SIH, it is important to enquire about any history of lumbar puncture, epidural or spinal anaesthesia, or of spinal surgery.

Orthostatic headache is present in some patients with postural tachycardia syndrome or orthostatic hypotension, sometimes as the predominant symptom of orthostatic intolerance. These diagnoses should be

considered in cases with normal imaging; they can be screened for using an active stand test and confirmed by autonomic testing.

Orthostatic headache can also be confused with motion sensitivity in migraine, and position-related headache in cervicogenic headache, so it is important to confirm that the headache relates to the upright position, rather than to motion or neck position.

Radiological diagnosis of SIH

MR scan of brain should be performed as the first-line investigation of SIH and is essential to confirm the diagnosis. MR scan features of SIH include diffuse pachymeningeal enhancement, engorgement of venous sinuses, pituitary enlargement, brain sagging (effaced suprasellar and prepontine cisterns and reduced mammillopontine distance) and subdural hygroma/haematoma (see [figure 1](#)).¹³ Ideally, the MR scan of brain should be performed with gadolinium contrast; however, if that is not possible, neuroradiologists can often identify diffuse pachymeningeal thickening and hyperintensity on non-contrast fluid-attenuated inversion recovery sequences.¹⁴ As many as 20% of cases of SIH have normal brain MRI, and so normal imaging does not exclude the diagnosis.⁶

Whole-spine MRI rarely helps to identify the site of spinal CSF leakage. It is, however, useful to identify the presence or absence of a spinal longitudinal extradural CSF collection, which indicates the likely underlying cause of the CSF leak and guides the strategy for myelography if the patient does not respond to first-line treatment.

CSF pressure measurement

Low CSF pressure (<6 cm CSF) is included in International Headache Society diagnostic criteria for headache due to SIH.¹⁵ However, only one-third of patients with imaging-confirmed SIH have a CSF opening pressure of ≤6 cm CSF.¹⁶ Therefore, lumbar puncture should not be performed solely to check opening pressure, particularly as lumbar puncture involves dural puncture and may complicate the situation. Lumbar puncture may be performed for other purposes (eg, to exclude other causes of pachymeningeal thickening/enhancement), in which case, the opening CSF pressure should be measured, and finding a low pressure supports the diagnosis of SIH.

Invasive intraparenchymal intracranial pressure monitoring is occasionally used in patients with suspected SIH in specialist centres, but its sensitivity and specificity are not known, and are not recommended in the standard patient pathway.

'Conservative' and symptomatic management

The literature suggests that symptoms resolve with conservative treatment alone in 28% of patients with SIH. This usually comprises bed rest, hydration and/or caffeine administration.⁶ It is not recommended

Table 2 Differential diagnoses of SIH			
Differential diagnosis	Similarities to SIH	Difference to SIH	How to diagnose
Post-dural puncture headache	Similar symptoms as SIH (see table 1).	Precipitated by a specific intervention meaning the leak site is known and targeted treatment can be performed. MR scan of brain is usually normal in post-dural puncture headache, whereas it is abnormal in >80% of patients with SIH.	Enquiry about history of spinal procedures. Review previous medical records.
Postural tachycardia syndrome (PoTS)	Orthostatic headache occurs in 2–58% of patients with PoTS, ²⁷ sometimes as the predominant symptom. PoTS and SIH can coexist.	Headache is more commonly frontal/holocranial in PoTS, but occipital in SIH. Light-headedness and palpitations predominate in PoTS, compared with rotational vertigo, hearing impairment and tinnitus seen in SIH.	Enquiry about other symptoms of orthostatic intolerance. Active stand test or autonomic testing to document an increase of heart rate by at least 30 beats/min on standing. MR scan of brain for signs of SIH.
Migraine	Headache of SIH is often associated with migrainous features (nausea, photophobia, phonophobia). Migraine often improves on lying down. Migraine and SIH can coexist.	Motion sensitivity of headache in migraine relates to movement rather than posture. Any improvement on lying down in migraine is less reliable and immediate than in SIH.	History to confirm that headache is provoked by movement rather than posture, history of migraine attacks.
Primary new daily persistent headache	SIH can present with sudden-onset persistent headache without a predominant orthostatic quality.	SIH presenting as new daily persistent headache usually has an orthostatic quality soon after the onset, although this may become less noticeable over time.	Retrospective enquiry about orthostatic quality soon after the time of headache onset and other symptoms of SIH. MR scan of brain should be performed in all cases of new daily persistent headache to look for a secondary cause.
Cervicogenic headache	Occipital and neck/back pain often develop in SIH. Cervicogenic headache can improve on lying down.	Cervicogenic headache is provoked either by neck movement or neck position, rather than body posture.	History for headache triggers. Physical examination for cervical range of motion and myofascial tenderness. MR brain scan is usually abnormal in SIH and MR scan of cervical spine in cervicogenic headache often shows causative pathology.
Occipital neuralgia	SIH commonly causes occipital head pain.	Occipital neuralgia causes brief neuralgiform pain attacks, is not orthostatic and is not associated with other symptoms of SIH.	History of pain characteristics and associated symptoms.
Chiari malformation	Both are associated with occipital pain, neck pain and worsening with Valsalva manoeuvres. MR scan of brain shows cerebellar tonsillar descent in both conditions.	Headache is not orthostatic and there are no other MR scan features of SIH (see figure 1).	History for orthostatic quality of headache and review of MR brain scan features.
SIH, spontaneous intracranial hypotension.			

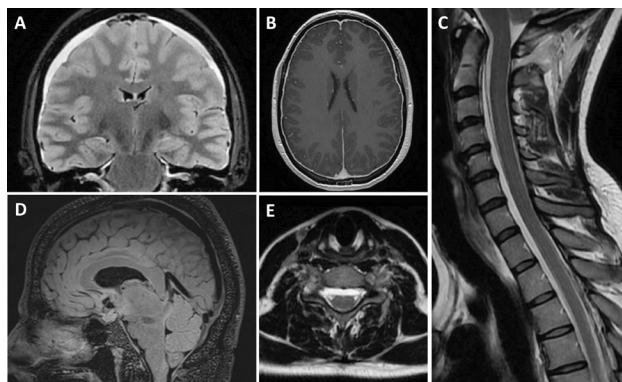


Figure 1 MR brain scan signs of SIH. (A) Coronal FLAIR sequence showing bilateral subdural collections. (B) Axial T1 post-contrast sequence showing generalised smooth dural enhancement. (C) Sagittal T2 of the cervical spine showing spinal longitudinal epidural collection. (D) Sagittal T2 SPACE sequence showing brain sagging and distension of venous sinuses. (E) Three-dimensional (3D) axial T2 CUBE (heavily T2-weighted 3D sequence) of the upper cervical spine in the same patient as image C showing ventral epidural collection. FLAIR, fluid-attenuated inversion recovery; SIH, spontaneous intracranial hypotension.

delaying epidural blood patch treatment with conservative management for any longer than 2 weeks from symptom onset⁵ for three reasons: 72% of patients do not respond to symptom management alone; symptoms can improve without radiological resolution of the leak (which remains associated with long-term

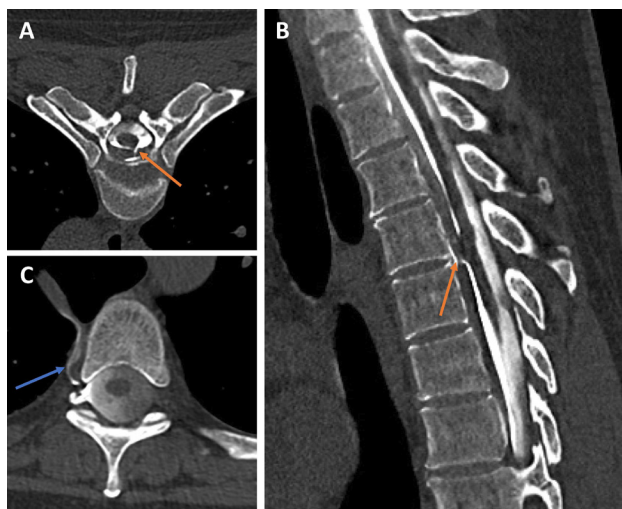


Figure 2 CSF leak and CSF venous fistula identified using CT myelography. Axial (A) and sagittal (B) sections from a hyperfast dynamic CT myelogram show an upper thoracic ventral leak. There is a jet of contrast extravasation at the intervertebral space (orange arrows). In a different patient (C), a lateral decubitus dynamic CT myelogram depicts a right-sided CSF venous fistula (blue arrow). Contrast extends from a root sleeve diverticulum into a right paraspinal segmental vein, and subsequently into the azygos vein (which in this case, lies in an azygos fissure). CSF, cerebrospinal fluid.

risks such as superficial siderosis) and early treatment of SIH gives greater likelihood of treatment response.¹⁷

Bed rest is usually the main factor that relieves patients' symptoms and should be encouraged where possible while waiting for spontaneous resolution, or for specific investigation and treatments to be performed.

Other approaches, which are safe but have unknown benefits, include encouraging good hydration, avoiding Valsalva manoeuvres (such as coughing, straining or heavy lifting) and using an abdominal binder.

Pharmacological treatment of orthostatic headache and other symptoms of SIH is rarely effective, and management should focus on diagnosis and treatment of the underlying spinal CSF leak. Analgesics such as paracetamol and/or non-steroidal anti-inflammatory drugs may be trialled, and occasionally, opioid medication is required, but their routine use should be avoided. Anti-emetics may be required for symptomatic management of nausea and vomiting.

Oral or intravenous caffeine may be used as part of symptomatic management of SIH, but its use should not delay the diagnosis and treatment of the underlying spinal CSF leak. Although there is no evidence for caffeine specifically in SIH, there is evidence in post-dural puncture headache.¹⁸

Epidural blood patches

Non-targeted epidural blood patch is the most common first-line intervention for SIH and should be offered to all patients within 2 weeks of symptom onset. An estimated 64% of patients respond to the first non-targeted epidural blood patch.⁶

In practice, in most UK hospitals, obstetric anaesthetists have the expertise to perform blood patches, given their experience in performing these for post-dural puncture headache. Neuroradiologists may also perform non-targeted epidural blood patches in neuroscience centres using fluoroscopy or CT scan guidance.

The main difference between the headache of SIH and post-dural puncture headache is that in SIH, the site of CSF leak is unknown, and so requires a higher volume of blood. The evidence suggests that using over 20 mL of blood is more effective,^{19 20} and guidelines recommend giving 20–40 mL, as tolerated by the patient.⁵ Non-targeted epidural blood patch for SIH can be performed at a single (lumbar) level or divided between two levels (lumbar and thoracic); the blood spreads throughout the entire epidural space and so can successfully treat spinal CSF leaks even if they are in the cervical region.²¹

Patients undergoing a non-targeted epidural blood patch should be informed of its potential risks and complications and advised to seek urgent medical attention if they develop any new symptoms. Common adverse effects include back pain, radicular irritation and post-treatment rebound headache. Serious adverse events are extremely rare, but include infection,

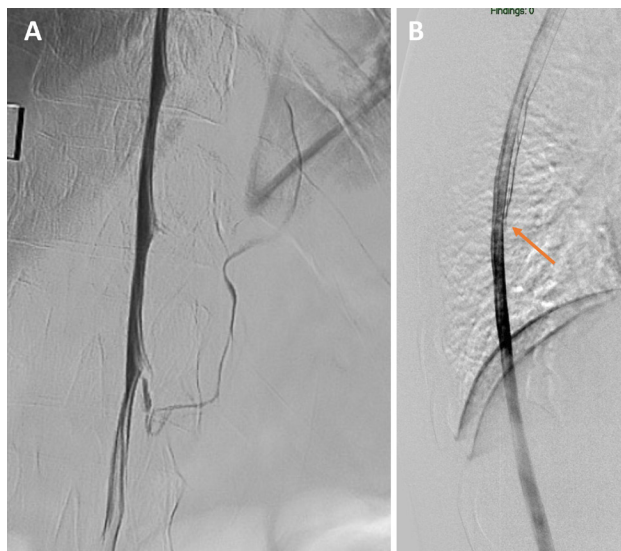

Figure 3 CSF leak and CSF venous fistula identified using digital subtraction myelography. Left T12 CSF venous fistula (A) shown on digital subtraction myelography with the patient in the left lateral decubitus position. Mid-thoracic ventral CSF leak (B) shown on prone digital subtraction myelography in a different patient. Acknowledgement for image A: Dr Patrick J Nicholson, Beaumont Hospital, Dublin, Ireland. Acknowledgement for image B: Dr Vikram Wadhwa, Cedars Sinai Medical Center, Los Angeles, USA. CSF, cerebrospinal fluid.

accidental dural puncture, cauda equina syndrome, spinal cord compression, neuropathic radicular symptoms and arachnoiditis.

Following non-targeted epidural blood patches, patients should be monitored as an inpatient for complications, for at least 2 hours, either supine or in the Trendelenburg position (to aid the cranial movement of blood in the epidural space), and they should be clinically reviewed before discharge. After discharge, they should be advised to lie flat for as much as possible for the next 24–72 hours, and to avoid Valsalva manoeuvres for the next 4–6 weeks. Patients should be followed up in approximately 2 weeks in order to assess the response and need for further intervention. If there is no response to a first non-targeted epidural blood patch, then it may be repeated 2–4 weeks later.⁵

After successful treatment of SIH, some patients develop a rebound headache, which often has a reverse orthostatic quality (ie, worse on lying flat and improved on being upright) suggesting intracranial hypertension. Usually, there are no objective signs of intracranial hypertension (such as papilloedema) and the headache is self-limiting, but occasionally clinicians use medications such as acetazolamide.

Radiological identification of spinal CSF leak site

Investigations to identify the specific leak site are invasive and usually reserved for the minority of patients

who do not respond to at least one non-targeted epidural blood patch.

Contrast-enhanced myelography with either dynamic CT myelography or digital subtraction myelography is the optimal investigation to identify the site of spinal CSF leak or CSF venous fistula in order to plan targeted treatment.

The choice of myelographic technique depends on the presence or absence of a spinal longitudinal epidural collection. Finding such a collection suggests a leak from a dural tear allowing CSF to escape rapidly into the epidural space. Often, this is ventral and caused by a discogenic microspur, and images need to be taken immediately following contrast injection or otherwise may miss the point of CSF egress. This requires hyperfast CT myelography or digital subtraction myelography (see figures 2 and 3). Positioning of the patient for the first set of images should depend on the distribution of the spinal longitudinal epidural collection (ie, prone for a ventral collection). Dural tears can also occur dorsal to and lateral to the spine.

If there is no spinal longitudinal epidural collection, then a CSF venous fistula is the most likely cause. This is an abnormal connection between the spinal subarachnoid space and a paraspinal vein (or network of veins), which causes loss of CSF directly into the venous system. CSF venous fistulas are most commonly found in the lower thoracic region, but can also occur in cervical and lumbar regions.²² They usually arise from the nerve root sleeve at the site of a meningeal diverticulum and are most easily identified when myelography is performed in the lateral decubitus position on the side of the CSF venous fistula (see figures 2 and 3). Therefore, if there is no spinal longitudinal epidural collection, the patient should then undergo a lateral decubitus CT myelogram or lateral decubitus digital subtraction myelogram (on both sides). There are no studies comparing CT myelography with digital subtraction myelography, so the technique with which the operator has more experience should usually be used first.

Conventional myelography—where images are taken several minutes after injecting contrast—is unlikely to identify the leak site. Dynamic CT myelography and digital subtraction myelography are best performed by experienced neuroradiologists in a high-volume specialist centre.

MR myelography with off-label intrathecal injection of gadolinium myelography is occasionally used but lacks temporal resolution and so is not routinely recommended.

Targeted treatments

Having identified the site of leak, targeted treatment can be performed, with a high chance of successfully treating the underlying CSF leak or CSF venous fistula. A dural tear may be treated either with image-guided targeted blood and/or fibrin glue patching or with

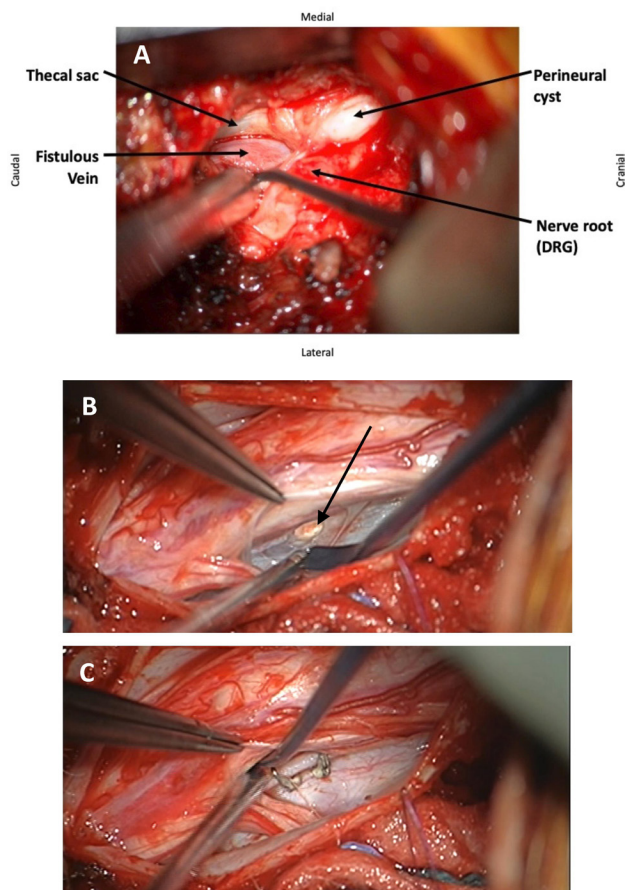


Figure 4 Surgical images of CSF venous fistula as visualised from paraspinal approach at time of surgery (A). Ventral dural defect seen during surgery (B) and repaired using clips (C). CSF, cerebrospinal fluid; DRG, dorsal root ganglion.

surgery. A CSF venous fistula may be treated either with transvenous embolisation, targeted blood and/or fibrin glue patching, or surgery. The choice of treatment depends on technical aspects, operator experience and patient preference. Thus, targeted treatments are best performed in a specialist centre, where each of the above treatments is available and there is a multidisciplinary meeting to discuss benefits and risks of each treatment option. **Figure 4** shows examples of CSF venous fistula and ventral dural defect as seen during surgery.

MRI-negative patients

Up to 20% of patients with presumed SIH have normal neuroimaging.⁶ However, it is rare to find a CSF leak or CSF venous fistula in patients with normal imaging using current myelographic techniques.^{23 24}

In a patient with a clinical diagnosis of SIH but normal MRI of brain and spine, it is important to confirm with a neuroradiologist that neuroimaging is in fact normal. General radiologists have limited exposure and confidence in interpreting imaging for suspected SIH,⁴ and in some patients with SIH, the

MR brain scan is initially reported as normal but retrospectively recognised as having features of SIH.³

It is also important to reconsider differential diagnoses such as postural tachycardia syndrome, migraine and cervicogenic headache.

If imaging is truly negative, but there is still a high clinical suspicion of SIH, then guidelines suggest that the patient should be referred to a specialist centre for multidisciplinary team discussion and further management.⁵

Complications of SIH

There are several recognised complications of SIH, including subdural haematoma/hygroma, cerebral venous sinus thrombosis, superficial siderosis, bibrachial amyotrophy, syringomyelia secondary to pseudo-Chiari malformation, frontotemporal dementia-like syndrome due to brain sagging and coma.

Subdural collections in SIH probably arise from traction-related shearing of bridging veins due to brain sagging. They are usually bilateral, associated with typical SIH symptoms and develop without any other risk factors for subdural haematoma. Since the underlying mechanism is intracranial hypotension, the management should be targeted at the underlying leak. Drainage of the haematoma is not usually required, and if necessary, it will likely recur if the spinal CSF leak is not treated.

Cerebral venous sinus thrombosis in SIH most likely results from venous stasis caused by venous engorgement and turbulent flow from traction on venous structures. Patients require anticoagulation alongside treatment of the spinal CSF leak.²⁵

Superficial siderosis is a late complication of untreated SIH. For this reason, imaging of patients with SIH should include blood-sensitive sequences such as susceptibility-weighted imaging or gradient echo sequences. In one study, no patients had developed either superficial siderosis or bibrachial amyotrophy within 4 years of follow-up, but the rate was approximately 10% after 8 years, 33% after 12 years and 58% after 16 years.²⁶ Again, the management should focus on treatment of the spinal CSF leak.

Occasional patients are found incidentally to have radiographic evidence of SIH without typical clinical features. Such patients should be offered treatment and radiological follow-up in light of the long-term risk of irreversible superficial siderosis.

Management pathways

Guidelines recommend that patients with suspected SIH should be referred urgently to their local neurologist within 2–4 weeks, unless the patient cannot look after themselves or has had a rapid clinical deterioration or developed serious complications, in which case they require emergency assessment.⁵

Patients who do not respond to initial treatment with conservative management and non-targeted epidural

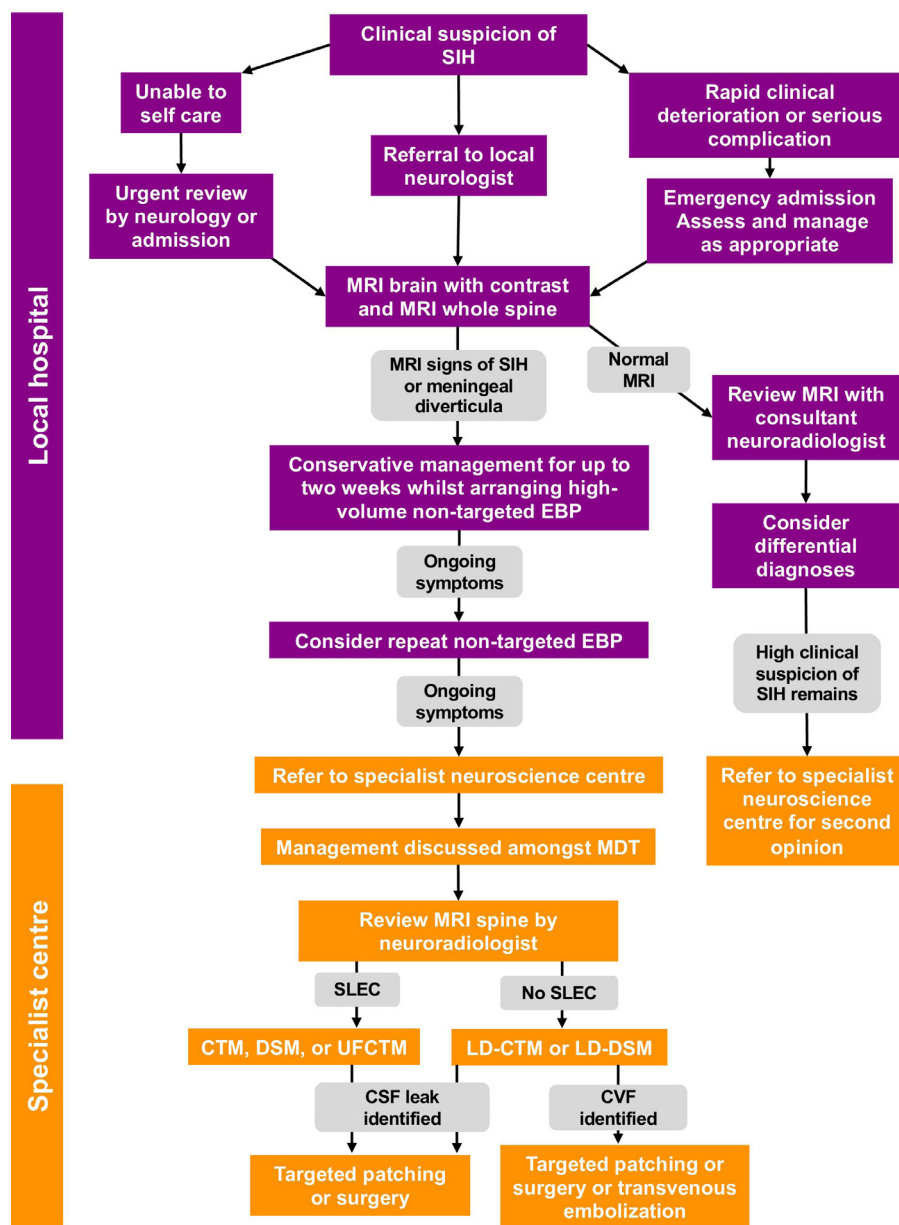


Figure 5 Management algorithm. Adapted from recent multidisciplinary consensus guidelines.⁵ CSF, cerebrospinal fluid; CTM, CT myelography; CVF, CSF venous fistula; DSM, digital subtraction myelography; EBP, epidural blood patch; LD-CTM, lateral decubitus CT myelography; LD-DSM, lateral decubitus digital subtraction myelography; MDT, multidisciplinary team; SIH, spontaneous intracranial hypotension; SLEC, spinal longitudinal extradural CSF collection; UFCTM, ultrafast CT myelography.

blood patch(es) should be referred to a specialist centre where there is a multidisciplinary meeting and expertise to perform contrast-enhanced myelography, targeted patching and/or transvenous embolisation, and surgery.

Follow-up

All patients receiving intervention should be followed up within 48 hours to exclude early complications. As patients are advised to lie flat as much as possible for the first 1–3 days, although they may describe rebound headache and procedure-related localised discomfort in the back, it is not possible to assess treatment response reliably at this stage after patching. Following epidural blood patches, which have an approximately two-thirds chance

of success, guidelines therefore recommend follow-up after 10–14 days, and moving on to the next stage in management pathway if there is a lack of response. Following targeted treatment, which has a high chance of success, guidelines recommend follow-up at 3–6 weeks. At clinical follow-up, we assess: the time to headache onset after becoming upright, peak headache severity, severity of non-headache symptoms, time able to spend upright before needing to lie down and cumulative hours able to spend upright per day.

Patients with prolonged symptoms of SIH have usually had long periods of bed rest, which may have led to deconditioning and persistence of orthostatic intolerance. These

symptoms should also be assessed at follow-up and may require rehabilitation addressing skeletal muscle deconditioning and autonomic postural responses.

Following an improvement/resolution of symptoms of SIH after intervention, we recommend radiological follow-up with MRI, as it is not uncommon for symptoms to improve in absence of radiological improvement, implying an ongoing spinal CSF leak and associated risk of complications such as superficial siderosis.

CONCLUSION

SIH is a highly disabling, but treatable secondary cause of headache. It is diagnosed clinically based on orthostatic headache and associated symptoms, and radiologically using MR scan of brain with contrast. First-line treatment is with a high-volume non-targeted epidural blood patch. If there is no response to non-targeted epidural blood patch(es), the site and cause of spinal CSF leak site should be sought using dynamic CT myelography or digital subtraction myelography, in order to perform targeted treatment with surgery, targeted patching or transvenous embolisation. [Figure 5](#) shows a management algorithm, adapted from recent consensus guidelines.⁵

Key points

- ▶ Spontaneous intracranial hypotension (SIH) should be considered in any patient with orthostatic headache.
- ▶ The management of SIH should focus on identifying and treating the leak rather than non-specific symptomatic measures.
- ▶ Non-targeted epidural blood patch is the first-line treatment and should be performed as early as possible after symptom onset using at least 20 mL of blood.
- ▶ Patients who do not respond to one or two non-targeted epidural blood patches should be referred to a specialist centre for dynamic myelography to localise the site of leak and to facilitate targeted treatment.

Further reading

- ▶ Cheema S, Anderson J, Angus-Leppan H, *et al.* Multidisciplinary consensus guideline for the diagnosis and management of spontaneous intracranial hypotension. *J Neurol Neurosurg Psychiatry*. 2023. doi: 10.1136/jnnp-2023-331166.
- ▶ D'Antona L, Jaime Merchan MA, Vassiliou A, *et al.* Clinical Presentation, Investigation Findings, and Treatment Outcomes of Spontaneous Intracranial Hypotension Syndrome: A Systematic Review and Meta-analysis. *JAMA Neurol*. 2021;78(3):329–337.

Twitter Manjit Matharu @manjit_matharu

Acknowledgements Members of the UK SIH Specialist Interest Group who contributed to developing the consensus guidelines: Jane Anderson, Heather Angus-Leppan, Paul Armstrong, David Butteriss, Lalani Carlton Jones, David Choi, Amar Chotai, Linda D'Antona, Indran Davagnanam, Brendan Davies, Paul Dorman, Callum Duncan, Simon Ellis, Valeria Iodice, Clare Joy, Susie Lagrata, Sarah Mead, Danny Morland, Justin Nissen, Jenny Pople, Nancy Redfern, Parag Sayal, Daniel Scoffings, Russell Secker, Ahmed K Toma, Tamsin Trevarthen, James Walkden. International reviewers of the SIH consensus guideline: Jurgen Beck, Peter G Kranz, Wouter Schievink, Shuu-Jiun Wang. Professional bodies which reviewed the draft SIH consensus guideline: the Association of British Neurologists Headache and Pain Advisory Group; the British Association for the Study of Headache; the Royal College of Physicians; the Royal College of Physicians of Edinburgh; the Royal College of Anaesthetists; the Association of Anaesthetists; the Obstetric Anaesthetists Association.

Contributors SC—drafting and revision of manuscript and creation of figures. DM—revision of clinical aspects of the manuscript. AQ—providing myelographic images and revision of radiological aspects of the manuscript. PS—providing surgical images and revision of surgical aspects of the manuscript. SK—revision of clinical aspects of the manuscript. ID—revision of radiological aspects of the manuscript. MM—conception of the review and revision of the manuscript. All authors have reviewed and approved of the final submitted manuscript.

Funding The authors have not declared a specific grant for this research from any funding agency in the public, commercial or not-for-profit sectors.

Competing interests SC received research fellowship sponsored by Abbott. DM received research fellowship sponsored by Medtronic. SK, ID, AQ and PS—none. MM—chair of the medical advisory board of the CSF Leak Association, serves on the advisory board for Abbott, Allergan, Novartis, Eli Lilly, Medtronic, Autonomic Technologies and TEVA, and has received payment for the development of educational presentations from Allergan, electroCore, Eli Lilly, Novartis and TEVA.

Patient consent for publication Not required.

Ethics approval Not applicable.

Provenance and peer review Commissioned. Externally peer reviewed by Nick Silver, Liverpool, UK.

Data availability statement No data are available.

Open access This is an open access article distributed in accordance with the Creative Commons Attribution Non Commercial (CC BY-NC 4.0) license, which permits others to distribute, remix, adapt, build upon this work non-commercially, and license their derivative works on different terms, provided the original work is properly cited, appropriate credit is given, any changes made indicated, and the use is non-commercial. See: <http://creativecommons.org/licenses/by-nc/4.0/>.

ORCID iD

Manjit Matharu <http://orcid.org/0000-0002-4960-2294>

REFERENCES

- 1 Pradeep A, Madhavan AA, Brinjikji W, *et al.* Incidence of spontaneous intracranial hypotension in Olmsted County, Minnesota: 2019–2021. *Interv Neuroradiol* 2023;15910199231165429.
- 2 Schievink WI, Maya MM, Moser FG, *et al.* Incidence of spontaneous intracranial hypotension in a community: Beverly Hills, California, 2006–2020. *Cephalalgia* 2022;42:312–6.

- 3 Cheema S, Joy C, Pople J, *et al.* Patient experience of diagnosis and management of spontaneous intracranial hypotension: a cross-sectional online survey. *BMJ Open* 2022;12:e057438.
- 4 Cheema S, Anderson J, Duncan C, *et al.* Survey of healthcare professionals' knowledge, attitudes and practices regarding spontaneous intracranial hypotension. *BMJ Neurol Open* 2022;4:e000347.
- 5 Cheema S, Anderson J, Angus-Leppan H, *et al.* Multidisciplinary consensus guideline for the diagnosis and management of spontaneous intracranial hypotension. *J Neurol Neurosurg Psychiatry* 2023;94:835–43.
- 6 D'Antona L, Jaime Merchan MA, Vassiliou A, *et al.* Clinical presentation, investigation findings, and treatment outcomes of spontaneous intracranial hypotension syndrome: a systematic review and meta-analysis. *JAMA Neurol* 2021;78:329–37.
- 7 Mea E, Chiapparini L, Savoirdo M, *et al.* Application of IHS criteria to headache attributed to spontaneous intracranial hypotension in a large population. *Cephalalgia* 2009;29:418–22.
- 8 Leep Hunderfund AN, Mokri B. Second-half-of-the-day headache as a manifestation of spontaneous CSF leak. *J Neurol* 2012;259:306–10.
- 9 Mokri B. Spontaneous intracranial hypotension. *Continuum (Minneapolis)* 2015;21:1086–108.
- 10 Schievink WI, Wijdicks EF, Meyer FB, *et al.* Spontaneous intracranial hypotension mimicking aneurysmal subarachnoid hemorrhage. *Neurosurgery* 2001;48:513–6.
- 11 Schievink WI. Spontaneous intracranial hypotension. *N Engl J Med* 2021;385:2173–8.
- 12 Capizzano AA, Lai L, Kim J, *et al.* Atypical presentations of intracranial hypotension: comparison with classic spontaneous intracranial hypotension. *AJNR Am J Neuroradiol* 2016;37:1256–61.
- 13 Dobrocky T, Grunder L, Breiding PS, *et al.* Assessing spinal cerebrospinal fluid leaks in spontaneous intracranial hypotension with a scoring system based on brain magnetic resonance imaging findings. *JAMA Neurol* 2019;76:580–7.
- 14 O'Carbhaill RM, Haughey AM, Willinsky RA, *et al.* The presence of pachymeningeal hyperintensity on non-contrast flair imaging in patients with spontaneous intracranial hypotension. *Neuroradiology* 2023;65:893–8.
- 15 Headache classification committee of the international headache society (IHS) the international classification of headache disorders, 3rd edition. *Cephalalgia* 2018;38:1–211.
- 16 Kranz PG, Tanpitukpongse TP, Choudhury KR, *et al.* How common is normal cerebrospinal fluid pressure in spontaneous intracranial hypotension? *Cephalalgia* 2016;36:1209–17.
- 17 Häni L, Fung C, Jesse CM, *et al.* Outcome after surgical treatment of cerebrospinal fluid leaks in spontaneous intracranial hypotension—a matter of time. *J Neurol* 2022;269:1439–46.
- 18 Basurto Ona X, Uriona Tuma SM, Martínez García L, *et al.* Drug therapy for preventing post-dural puncture headache. *Cochrane Database Syst Rev* 2013;2013:CD007887.
- 19 Wu J-W, Hseu S-S, Fuh J-L, *et al.* Factors predicting response to the first epidural blood patch in spontaneous intracranial hypotension. *Brain* 2017;140:344–52.
- 20 Pagani-Estévez GL, Cutsforth-Gregory JK, Morris JM, *et al.* Procedural predictors of epidural blood patch efficacy in spontaneous intracranial hypotension. *Reg Anesth Pain Med* 2019:rapm-2018-000021.
- 21 Ferrante E, Arpino I, Citterio A. Is it a rational choice to treat with lumbar epidural blood patch headache caused by spontaneous cervical CSF leak? *Cephalalgia* 2006;26:1245–6.
- 22 Kranz PG, Gray L, Malinzak MD, *et al.* CSF-venous fistulas: anatomy and diagnostic imaging. *AJR Am J Roentgenol* 2021;217:1418–29.
- 23 Schievink WI, Maya M, Prasad RS, *et al.* Spontaneous spinal cerebrospinal fluid-venous fistulas in patients with orthostatic headaches and normal conventional brain and spine imaging. *Headache* 2021;61:387–91.
- 24 Kim DK, Carr CM, Benson JC, *et al.* Diagnostic yield of lateral decubitus digital subtraction myelogram stratified by brain MRI findings. *Neurology* 2021;96:e1312–8.
- 25 Zhang D, Wang J, Zhang Q, *et al.* Cerebral venous thrombosis in spontaneous intracranial hypotension: a report on 4 cases and a review of the literature. *Headache* 2018;58:1244–55.
- 26 Schievink WI, Maya M, Moser F, *et al.* Long-term risks of persistent ventral spinal CSF leaks in SIH: superficial siderosis and bibrachial amyotrophy. *Neurology* 2021;97:e1964–70.
- 27 Ray JC, Pham X, Foster E, *et al.* The prevalence of headache disorders in postural tachycardia syndrome: a systematic review and meta-analysis of the literature. *Cephalalgia* 2022;42:1274–87.