



YOUNG STROKE'S DOUBLE JEOPARDY

Those people unlucky enough to develop a 'young stroke' also have a higher mortality decades later. One-fifth of adults aged under 50 when they had their first transient ischaemic attack or stroke died within 20 years; 959 consecutive patients who survived the first month of stroke were studied. The increased mortality was higher in men. Half of the deaths were of vascular aetiology and cardioembolic stroke was the strongest predictor of premature mortality.

JAMA 2013;309:1136–44.

CHUCKING A WHITEY IN FLIGHTY

Is there a neurologist on this flight? There are 2.75 billion airline passengers a year, but there is a medical emergency on as few as 1 in 604 flights. The commonest reasons for seeking medical attention are syncope and presyncope (37.4%) but this rarely causes aircraft diversion (5.0%). Seizures occurred much less frequently (5.8% of emergencies) but more commonly caused aircraft diversion (12.0%). Possible stroke (2%) and headache (1%) were much less common emergencies.

Epileptologists will not be surprised to learn that passengers are prone to fainting on aircraft.

N Engl J Med 2013;368:2075–83.

S-100 β PREDICTS THE FUTURE

Neurologists can be called to the intensive care unit to prognosticate on people with moderate or severe brain injury. They may be blessed with a little acumen, a scan and an electroencephalogram, but no crystal ball. A meta-analysis of the role of a biomarker (seen in blood and cerebrospinal fluid) hoped to add clarity to the situation. One measurement on S-100 β (the β subunit of a calcium-binding protein present mainly in glial and Schwann cells) within 24 h of the injury predicted an unfavourable end result. This association was true for short-term and long-term outcomes. When taken in the context of other clinical factors, it may be even more powerful.

BMJ 2013;346:f1757

PLEASE DE-CYST!

On a worldwide basis, neurocysticercosis is a common and treatable cause of epilepsy; providing you have access to albendazole. A 42-year-old man from Vietnam

presented with multifocal seizures and had over 300 palpable intramuscular cysts (figure 1A) and 3 years of worsening headaches (CT scan, figure 1B). A subcutaneous biopsy identified a scolex with suckers and hooklets, typical of the *Taenia solium* tapeworm.

N Engl J Med 2013;368:2125

DRUMMER'S ANTHRAX

There is nothing that A Fo Ben likes more than to warn neurologists about dramatic poisonings from a trivial sources; it was with glee, therefore, that I discovered the advice of the US Centers for Disease Control and Prevention for animal hide drummers. Exposure to anthrax spores occurs through prolonged use (often 10 h or more) of untreated goatskin instruments. Although the risk of developing anthrax is small, the outcome can be catastrophic: three of the five cases between 2006 and 2008 in the US were fatal.

<http://www.bt.cdc.gov/agent/anthrax/faq/pelt.asp>

<http://www.cdc.gov/mmwr/preview/mmwrhtml/mm5928a3.htm>

► Additional references are published online only. To view please visit the journal online (<http://dx.doi.org/10.1136/practneurol-2013-000642>).

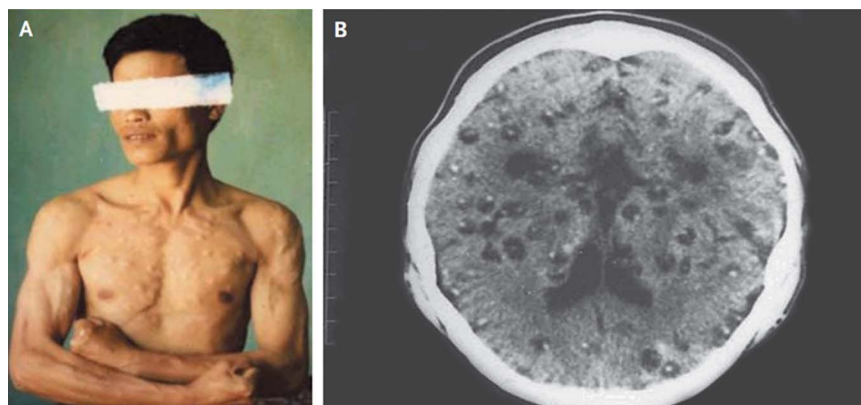


Figure 1 The florid dermatological and radiological features of neurocysticercosis. Image reproduced from *N Engl J Med* 2013; 368:2125.