



OPEN ACCESS

A practical approach to, diagnosis, assessment and management of idiopathic intracranial hypertension

Susan P Mollan,¹ Keira A Markey,² James D Benzimra,¹ Andrew Jacks,¹ Tim D Matthews,¹ Michael A Burdon,¹ Alex J Sinclair^{2,3}

¹Birmingham Neuro-Ophthalmology Unit, Ophthalmology Department, University Hospitals Birmingham NHS Trust, Queen Elizabeth Hospital Birmingham, Birmingham, UK

²Neurotrauma and Neurodegeneration, School of Clinical and Experimental Medicine, College of Medical and Dental Sciences, The Medical School, The University of Birmingham, Birmingham, UK

³Department of Neurology, University Hospital Birmingham NHS Trust, Queen Elizabeth Hospital Birmingham, Birmingham, UK

Correspondence to

Dr Alex J Sinclair,
Neurotrauma and Neurodegeneration, School of Clinical and Experimental Medicine, College of Medical and Dental Sciences, The Medical School, The University of Birmingham, Wolfson Drive, Edgbaston, Birmingham, B15 2TT, UK;
a.b.sinclair@bham.ac.uk

Published Online First
8 May 2014



Open Access
Scan to access more
free content



CrossMark

To cite: Mollan SP, Markey KA, Benzimra JD, et al. *Pract Neurol* 2014;**14**:380–390.

ABSTRACT

Adult patients who present with papilloedema and symptoms of raised intracranial pressure need urgent multidisciplinary assessment including neuroimaging, to exclude life-threatening causes. Where there is no apparent underlying cause for the raised intracranial pressure, patients are considered to have idiopathic intracranial hypertension (IIH). The incidence of IIH is increasing in line with the global epidemic of obesity. There are controversial issues in its diagnosis and management. This paper gives a practical approach to assessing patients with papilloedema, its investigation and the subsequent management of patients with IIH.

INTRODUCTION

Idiopathic intracranial hypertension (IIH) is becoming increasingly prevalent in line with the global epidemic of obesity.¹ In the UK, 22.7% of people are obese (Body Mass Index >30 kg/m²), while obesity throughout the world has doubled since 1980. Clinicians' attitudes to IIH vary: in our experience, only a minority of patients are at high risk of rapid visual loss.² The previously quoted figure of 25% developing severe permanent visual loss is probably an overestimate.² The reality for patients is that it is a chronic condition characterised by significantly disabling headaches and psychological morbidity.

The nomenclature for IIH has changed over the years: previous names being serous meningitis, pseudotumour cerebri or benign intracranial hypertension. The latter became inappropriate with awareness that this is not a benign condition, given the risk of visual loss and disabling chronic headaches. Pseudotumour cerebri is becoming increasingly popular as a

term to encompass primary raised intracranial pressure where there is no identifiable cause—which we term IIH—and secondary causes of raised pressure.³

The diagnostic criteria of IIH are well known and have evolved since Dandy's initial description in 1937⁴; they include a CSF opening pressure of ≥ 25 cm H₂O (box 1).³ However, these criteria recommend imaging only to exclude a venous sinus thrombosis in patients without the typical IIH phenotype (obesity and female sex). We feel, however, that it is essential to exclude venous sinus thrombosis (using MRI or CT with venography) in all patients presenting with pseudotumour cerebri, since being female and obese does not preclude the diagnosis of venous sinus thrombosis. The diagnosis can be difficult and the consequences of error can lead either to the neglect of a serious treatable cause of raised intracranial pressure, blindness or inappropriate treatment of patients who do not have IIH. Although there is insufficient literature to generate an evidence-based management strategy for IIH,⁵ experienced clinicians can manage it well.

AN APPROACH TO PAPILLOEDEMA

Patients generally present to the emergency department after an optometrist or family doctor detects papilloedema. They may or may not have other symptoms. Because papilloedema indicates potentially serious underlying disease, the purpose of the visit is to recognise and confirm the presence of papilloedema and arrange appropriate onward investigation. An important issue is that, in the UK, the most junior and inexperienced doctor often assesses the patient first to confirm the clinical finding of papilloedema. Once

Box 1 Diagnostic criteria for adult IIH*

- ▶ Papilloedema.
- ▶ Normal neurological examination except for cranial nerve abnormalities.
- ▶ Neuroimaging: Normal brain parenchyma without hydrocephalus, mass or structural lesion and no abnormal meningeal enhancement or venous sinus thrombosis on MRI and MR venography; if MRI is unavailable or contraindicated, contrast-enhanced CT may be used.
- ▶ Normal CSF composition.
- ▶ Elevated CSF opening pressure (≥ 25 cmH₂O) in a properly performed lumbar puncture.
- ▶ A diagnosis of IIH is definite in patients fulfilling A–E; the diagnosis is probable if A–D are met but the CSF pressure is lower than specified.

*Adapted from the 2013 revised diagnostic criteria for IIH.³

an ophthalmologist (of any grade) labels the patient as having papilloedema, this is rarely questioned further, and the pathway of investigations moves forward. Recognising papilloedema is usually straightforward (figure 1) but occasionally it can be very difficult to distinguish papilloedema from congenitally anomalous discs and pseudopapilloedema (figure 2). Where there is diagnostic difficulty, it is best to seek early assessment by neuro-ophthalmology, or a senior ophthalmologist with experience in differentiating swollen from apparently swollen optic discs. This avoids invasive investigations in the normal patient.

Case 1—Are you sure it is papilloedema?

A 23-year-old right-handed woman was referred by her optician to the emergency unit with longstanding headaches and swollen optic discs. Since the age of 12 years, she had experienced frequent headaches and recently had developed continuous tinnitus. She had no previous medical or ocular history and currently took no medication. On examination, her Body Mass Index was 36 kg/m². Her visual acuities were 6/6 bilaterally, aided with a small hypermetropic correction (right eye +1.75 diopters sphere and left eye +1.25 diopters sphere). She was already dilated after seeing the optician and the emergency doctor noted nasal disc margin blurring. She underwent normal neuro-imaging (MRI and MR venogram). Her lumbar puncture opening pressure was 26 cm CSF with normal constituents. She was discharged on oral acetazolamide 250 mg four times daily with a routine outpatient appointment for neuro-ophthalmology. Her disc photos showed small anomalous discs, and the visual field showed a typical clover leaf appearance, suggesting difficulty producing a reliable field. (Figure 3).

CLUES FROM THE HISTORY

Headaches are common and can be highly variable (see later). They may be of new onset or more chronic, particularly in those with previous migraine. Visual symptoms include blurred or double vision. Patients can describe transient loss of vision and/or 'greying out' of vision: so-called 'transient visual obscurations'. They usually relate to postural changes; and are usually brief, typically only seconds. Patients may report horizontal diplopia from a false-localising abducens nerve palsy. There may be pulsatile tinnitus—a rhythmic 'whooshing' sound heard in either or both ears synchronous with the patient's heartbeat, and often present only on lying down. Many patients do not volunteer this symptom unless directly asked.

CLUES FROM THE EXAMINATION

Clinicians should examine visual function (table 1) and extraocular movements in all cases.

Distinguishing pseudopapilloedema from papilloedema

This requires clinical experience. Pseudopapilloedema may be due to congenitally anomalous discs, optic nerve head drusen or a combination of the two. Congenitally anomalous discs are small nerves that lack a physiological cup. Optic nerve head drusen are globular hyaline bodies, which may be calcified. They are often seen incidentally during routine eye tests and up to 2% of the general Caucasian population may have them. Sometimes, they are obvious (figure 4). However, they are difficult to see when buried, the only clue being increased retinal vessel branching at the optic nerve head (figure 5). Ophthalmic ultrasound scanning (figure 6) can confirm their presence. Very occasionally when there is still diagnostic doubt such as, 'are these congenitally anomalous discs swollen?' fundus fluorescein angiography can help to determine if there is disc leakage (figure 7).

It can be extremely difficult to distinguish pseudopapilloedema from papilloedema and, where there is uncertainty, clinicians must keep an open mind. Inappropriately labelling pseudopapilloedema as IIH can have significant negative implications, and we have seen these cases complicated by morbidity from surgical shunting and the side effects of acetazolamide.

INVESTIGATION

Having identified papilloedema, it is essential to record blood pressure to exclude malignant hypertension. Patients then need urgent neuroimaging: this has two purposes, to identify any space-occupying lesion and to exclude a venous sinus thrombosis. The preferred imaging method is an MR scan of the head and orbits with intravenous contrast and MR venogram; these should, ideally, include fat suppression sequences, as these better define the intraorbital optic nerves. However, if this is not readily available, a CT head scan with a CT venogram will exclude most

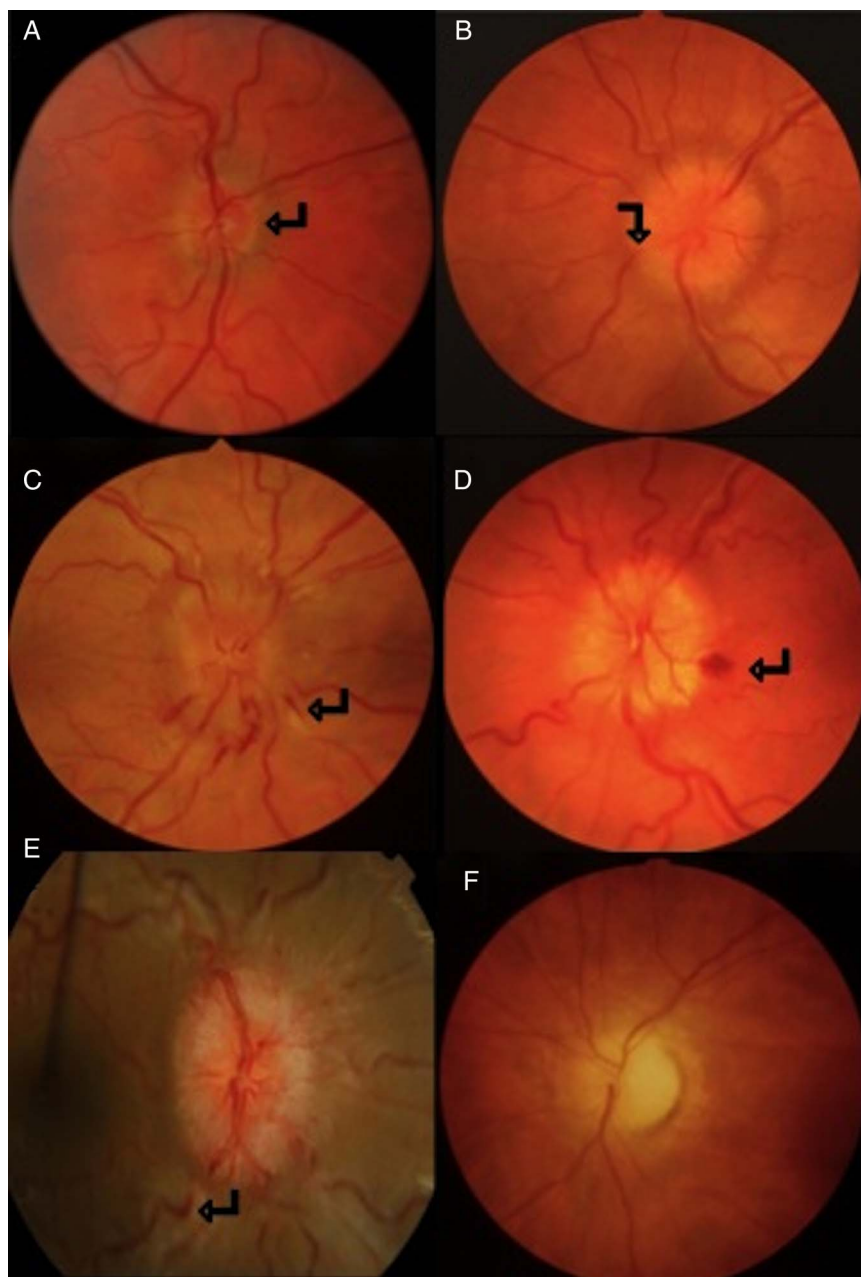


Figure 1 Single colour fundus photographs of patients with disc swelling secondary to raised intracranial pressure (papilloedema). (A) Mild papilloedema with burring and elevation of nasal disc margin (arrow). (B) Moderate papilloedema with obscuration of vessels by oedematous nerve fibre layer. (C, D, E) Severe papilloedema with cotton wool spots, nerve fibre layer haemorrhage (arrows C and D) and venous engorgement and tortuosity (arrow E). (F) Papilloedema with secondary optic atrophy. Note, as atrophy progresses, fewer nerve fibres can swell.

space-occupying lesions, cerebral venous sinus thrombosis and Chiari malformation. There are several possible radiological signs of IIH, although none is pathognomonic (figure 8). There may be an empty sella, a partially empty sella, decreased pituitary height or transverse sinus narrowing. In the orbits, the optic nerve sheath complex may be enlarged, the posterior globe flattened and occasionally the optic nerve head protruded.⁴

After excluding a structural intracranial lesion, patients require a lumbar puncture, performed with the patient in the lateral decubitus position. The opening

pressure is important, so every effort should be made to ensure all equipment is at hand; this includes having more than one packet of manometer tubes to avoid being unable to measure a pressure >40 cm CSF. The patient must be comfortable, as Valsalva, talking, crying and flexed legs compressing an obese abdomen, may artificially raise the pressure reading. We suggest slightly straightening the patient's legs at the hips to avoid compressing the intra-abdominal cavity. The column of CSF in the manometer needs sufficient time to settle—there should be small oscillations with breathing—before recording the reading. Our review on a practical

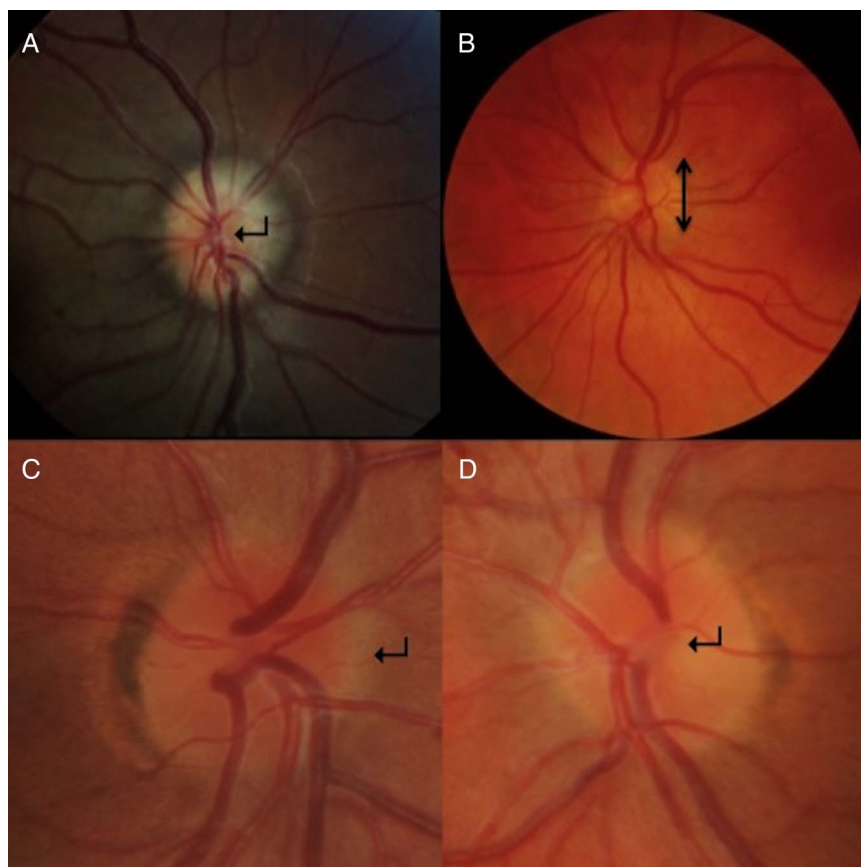


Figure 2 Single colour fundus photographs of pseudopapilloedema in patients initially thought to have IIH. (A) Elevated, lumpy disc with anomalous vascular pattern including trifurcation of central retinal artery (arrow) seen in optic nerve drusen. (B) Small disc height (arrow) leads to a crowded appearance of the optic nerve without a physiological cup. (C and D) High magnification photographs of right and left eyes of a patient with anomalous discs which show the indistinct nasal disc margin (arrow C) and absent physiological cup (arrow D).

approach to lumbar puncture has more tips.⁵ Despite optimising the conditions for lumbar puncture, it is still a one-off reading. CSF pressure varies diurnally, so a snapshot recording is not the whole story. It is, however, useful retrospectively to ask the patient if their symptoms (obscurations, headache, etc) improved for a few days after the lumbar puncture. Confirming a temporary improvement supports there being raised intracranial pressure. If the lumbar puncture is technically challenging, fluoroscopic or ultrasound guidance may help. A CSF sample should be sent for microscopy, protein and glucose (and sometimes for xanthochromia and culture to identify secondary causes of raised intracranial pressure, such as CSF hypercellularity, eg, subarachnoid haemorrhage and meningitis). Patients should also have blood taken to exclude anaemia,⁶ to check serum calcium, plasma glucose and renal function.

There is some debate about the limits of normal lumbar CSF opening pressure. Whiteley *et al*'s clinical study found the normal range for lumbar CSF opening pressure was 10–25 cm CSF (95% reference interval); but some normal subjects had opening pressures of up to 28 cm CSF.⁷ Furthermore, there is only a weak, non-significant relationship between Body Mass Index and

lumbar puncture opening pressure.⁷ In our experience, a common mistake is putting too much emphasis on a single reading, as normal people may have artificially high or low CSF pressures. When the clinical findings are out of keeping with the opening pressure, the pressure should be questioned and, in some cases, the lumbar puncture repeated. Occasionally, a CSF infusion study can help. However, we would recommend that all patients being evaluated for IIH whose lumbar pressure is ≥ 25 cm CSF should see an experienced neurologist or ophthalmologist to weigh up the evidence towards a diagnosis of IIH.

Children with IIH often present differently to adults, although this is beyond the scope of this article. In other atypical cases, such as non-obese women or men, where there is no underlying systemic cause for raised intracranial pressure (see differential diagnosis), we suggest extracranial imaging to exclude pathology, such as internal jugular vein obstruction.

DIFFERENTIAL DIAGNOSIS

When there is papilloedema with symptoms and signs of raised intracranial pressure, it is important to obtain a thorough past history and system screen to

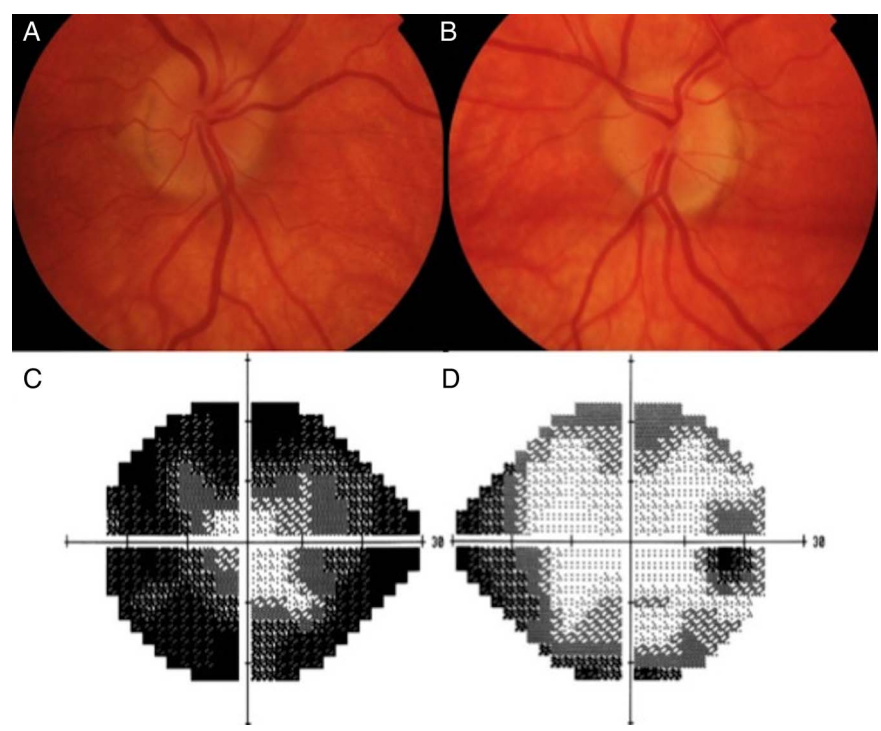


Figure 3 Case one: (A and B) Right and left colour fundus photographs of the optic nerve head showing small crowded discs with anomalous branching of the blood vessels. (C and D) Left and right grey-scale plot taken from the Humphrey visual field test printout, showing the 'clover leaf' pattern of an unreliable test performance.

identify treatable causes (box 2). Polycystic ovarian syndrome has a comorbid association with IIH, but current evidence suggests that it does not raise intracranial pressure.⁸

A comprehensive drug history is essential (table 2). Tetracyclines, nitrofurantoin and excessive vitamin A intake frequently appear in case reports as raising intracranial pressure, and their withdrawal often resolves the problem. It is possible that the previous use of high-dose oestrogen oral contraceptives may also contribute. This has been difficult to investigate as many cases are women of childbearing age, and therefore there is a high incidence of the use of these

medications in this age/sex group. If there is a strong temporal relationship between the oral contraceptive pill use and the diagnosis of IIH we may suggest stopping it. There is no evidence base here, but our practice is to suggest switching to a progesterone pill or barrier method. This requires careful management to avoid unplanned pregnancies. For patients with IIH wanting to start the oral contraceptive pill, we typically arrange more frequent review after starting it, but rarely note any problems.

Table 1 Mandatory visual function measurements

Visual acuity	Test each eye separately for the best corrected (with glasses) distance visual acuity, using either Snellen's or logMar chart. Use a pinhole to record improvement after correcting for refractive error
Colour vision	Test each eye individually with pseudoisochromatic plates, such as Ishihara's plates
Pupil examination	To exclude a relative afferent pupillary defect and oculosympathetic palsy (Horner's syndrome)
Visual field assessment	Assess visual fields (either a Humphrey's or Goldmann's), as confrontational visual fields picks up only gross defects
Dilated fundus examination	Document optic nerve head AND macular findings. This is important to exclude intraocular inflammation causing bilateral disc oedema. Ideally assess using a slit lamp.

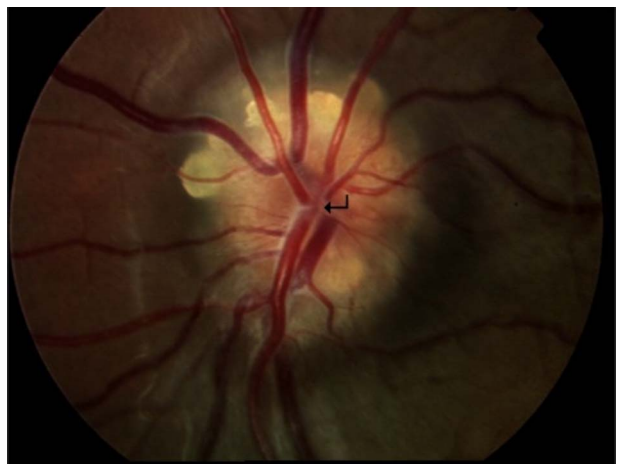


Figure 4 Surface and buried optic nerve head drusen. The disc is elevated and lumpy with visible yellowish deposits (drusen) within the optic nerve head. Note the absence of the physiological cup and anomalous vascular branching (arrow).

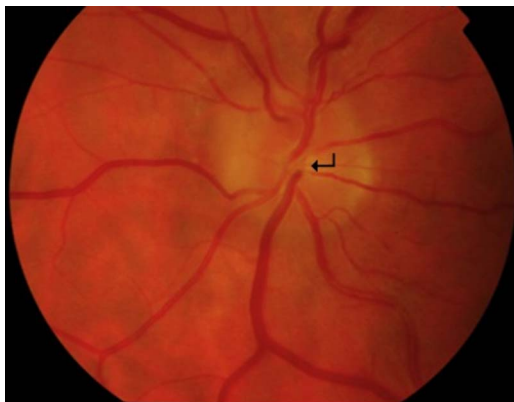

Figure 5 Colour fundus photograph of buried drusen. Elevated disc with absent physiological cup (arrow).

MONITORING IN IIH

Routine clinical observation involves monitoring of the visual function (table 1). Clinicians often ask what is the best technique for monitoring visual fields: at our unit, we use Humphrey visual fields as in Case 1, and Goldmann visual fields as in case 2. Patients need serial visual fields, and it is best to use the same form of perimetry each time. We prefer Humphrey in those patients capable of concentrating and completing the tests as it is sensitive and reproducible. However, it is important not to interpret a field based entirely on the grey-scale plot, and to consider the reliability indices (fixation losses, false positives and false negatives). A patient with inattention, or poor compliance with the test, may show a dramatic visual field deficit, as in Case 1, often with a high false-negative rate.

Goldmann visual fields can be performed on manual and automated machines. Typically, the periphery is plotted using a kinetic (moving) target, and the central visual field is tested statically. Manual perimetry using a Haag–Streit Goldmann perimeter requires a skilled operator; it is useful for neuro patients with serious visual loss, or those needing

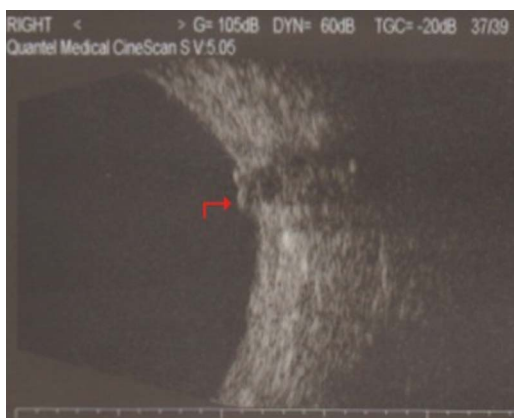

Figure 6 B-scan ultrasound of the right optic nerve, showing optic nerve head drusen. Ovoid echogenic foci in optic nerve (arrow).

significant supervision and encouragement to produce a reliable visual field. We find that non-organic visual loss is common in IIH, and so it is important to have a skilled operator who has time allowed for the patient.

Direct imaging of the optic nerve head is also useful in objectively assessing and longitudinally monitoring papilloedema and where there is fluid tracking to the macula. Colour fundus photography is an excellent way to record the fundal findings. Optical coherence tomography is becoming a superior technique, as it can measure swelling at the optic nerve head and the macula. Optical coherence tomography is very quick with the spectral (or Fourier) domain scan rate of at least 20 000 axial scans per second. It is non-invasive and provides high-resolution images with an axial resolution of 3–5 μm . Ultrasonographic B-scanning can also measure the optic disc height and the presence of excessive fluid within the optic nerve sheath (a surrogate marker of papilloedema).

MANAGEMENT

Disease evolution and outcomes in IIH are poorly characterised and are currently being evaluated in the National IIH:LIFE study (centres interested in participating should contact the author, AS). We have noted the following patient types:

- ▶ Those who rapidly lose vision at diagnosis over days to weeks (rare but vital to identify early).
- ▶ Those whose disease resolves following diagnosis, over weeks to months, occasionally after a single lumbar puncture (rare).
- ▶ Those at lower risk of visual loss who develop chronic disease with small fluctuations in disease activity, frequently with weight changes (the majority).
- ▶ Those in disease remission and off treatment.

For most patients, the clinical priority is to monitor vision and help the disease into remission. The headache symptoms typically comprise the greatest morbidity for these patients (see later). For patients in remission (the fourth cohort) with no papilloedema noted on visits over several years, we will aim to discharge and advise annual optometrist assessments, but return if any symptoms recur.

Management of acute visual loss in IIH

In high-risk patients with impending visual loss, some form of CSF divergence can be sight-saving. If the surgical procedure is likely to be delayed for 24–48 h, it is possible to insert a lumbar drain at the time of the lumbar puncture. The type of procedure depends on the local expertise and the neurosurgeon's preference. The clear immediate benefit is preserved vision, and sometimes reversal of visual loss (Case 2). Options include a lumboperitoneal shunt, where a catheter is inserted into the subarachnoid space at the lumbar spine between two vertebrae and fed around the oblique muscles under the skin into the peritoneum.

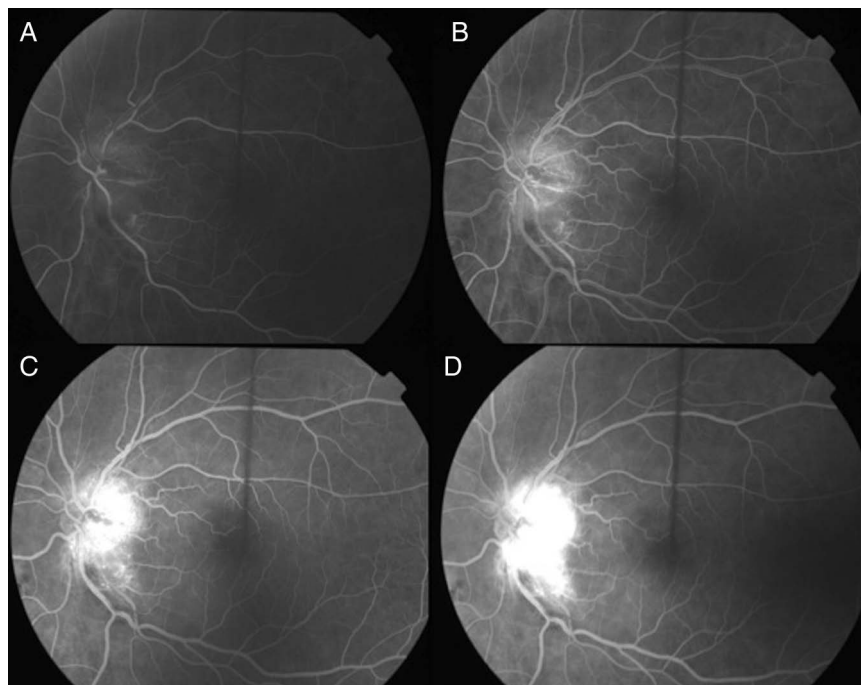


Figure 7 Fundus fluorescein angiography of the left eye with papilloedema. A rapid series of fundus photographs follow the intravenous injection of a fluorescent contrast agent. In true disc swelling, the frames (A–E) show progressively increased intensity and area of fluorescence at the disc. This shows fluorescein leakage from the oedematous disc.

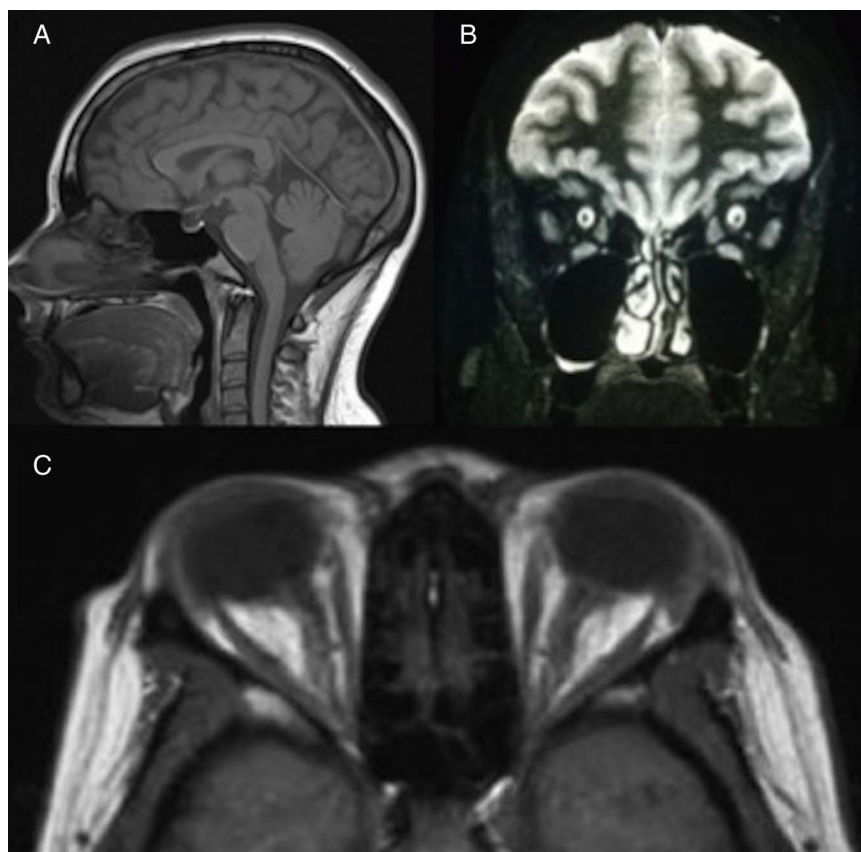


Figure 8 (A) MRI T1-weighted sagittal image showing a partially empty sella. (B) MRI T2-weighted coronal imaging showing increased fluid in the optic nerve sheath complex bilaterally. (C) MRI T1-weighted axial image showing flattening of the posterior globes, and dilated optic nerve sheaths in patient with raised intracranial pressure.

Box 2 Secondary causes of raised intracranial pressure for exclusion to diagnose IIH

- ▶ Secondary causes of raised intracranial pressure.
- ▶ Venous sinus thrombosis.
- ▶ Anaemia.
- ▶ Obstructive sleep apnoea.
- ▶ Drug-related.
- ▶ CSF hyperproteinaemia/hypercellularity, for example, spinal cord tumour/meningitis/Guillain–Barré syndrome/subarachnoid haemorrhage.
- ▶ Renal failure.
- ▶ Endocrine diseases, for example, Addison's/Cushing's/hypothyroidism.

We tend to avoid this in patients with low-lying cerebellar tonsils, as there is an increased risk of tonsillar descent following the shunt, with subsequent disabling cough headaches. A ventriculoperitoneal shunt diverts CSF from the lateral ventricle to the peritoneum. Less commonly, a ventriculoatrial shunt can divert CSF from the lateral ventricle to the atrium of the heart, or a ventriculopleural shunt diverts it to the pleural cavity. The surgical risks include shunt malfunction, infection and over-drainage. Over half the patients need shunt revision, and one-third need multiple revisions.⁹ We use shunting as a temporary measure to save vision in those at risk of impending visual loss. While the shunt is working, we advise weight reduction to put their disease into remission. Additionally, we almost never recommend shunting exclusively to treat headache, as this continues in most patients post-operatively (68% at 6 months and 79% at 2 years).⁹ Also, postoperative low-pressure headache occurs in 28%.⁹ We recommend using shunts with a valve system and CSF reservoir to reduce the morbidity from over-drainage and under-drainage.

Optic nerve sheath fenestration is an alternative for protecting the vision; however, it has little effect on the overall intracranial pressure and can lead to visual loss in inexperienced hands.

Table 2 Drugs associated with pseudotumour cerebri

Tetracycline/minocycline/ doxycycline	Corticosteroids (and withdrawal)
Nitrofurantoin	Beclometasone
Sulphonamides, for example, trimethoprim	Cimetidine
Nalidixic acid	Lithium
Vitamin A excess and retinoids	Tamoxifen
Depo Provera	Ciclosporin
Combined oral contraceptive pill	Non-steroidal anti-inflammatory drugs

Case 2

A 24-year-old woman presented with increasing blurring and 'greying' out of her left eye vision, particularly when bending over. She had a 3-week history of new onset headache, present on waking and of increasing severity. She reported a loud 'whooshing' noise in her left ear in the previous week. She had been previously well and her Body Mass Index was 34 kg/m². Visual acuity was 6/18 (right) and 1/60 (left). There was reduced colour vision in the left, with a relative afferent pupillary defect. There was extensive visual field loss in the left eye (figure 9). Her MR scan of brain and MR cerebral venogram were normal. The lumbar puncture opening pressure was 90 cm CSF, with normal constituents. She underwent a lumboperitoneal shunt within 24 hours of presentation. Her vision returned to 6/9 in both eyes, and her immediate post-operative fields were markedly improved.

Conservative management

Weight loss

Some patients volunteer recent weight gain before presentation, others do not, but weight loss is currently the only proven disease-modifying treatment for all overweight patients.^{10 11} Our recent prospective study highlighted that a 15% reduction of body weight, using a low calorie meal replacement liquid diet for 3 months, significantly reduced intracranial pressure, papilloedema and headaches.¹⁰ However, strategies to achieve long-term significant weight loss are notoriously difficult with typically as little as 2–4 kg of weight loss maintained at 2 years irrespective of the diet followed.¹² Many case reports describe the benefits of bariatric surgery in IIH.¹³ We are currently recruiting to a randomised controlled trial comparing efficacy and cost-effectiveness of the most effective community weight loss programme¹⁴ versus bariatric surgery.

Pharmacological management

Carbonic anhydrase inhibitors, such as acetazolamide, can provide symptomatic relief of raised intracranial pressure, although there is no evidence to support their benefit. Additionally, in the only randomised controlled trial looking at acetazolamide, over half the patients in the acetazolamide arm stopped treatment due to side effects.¹⁵ This aligns with our clinical experience that many cannot tolerate it. For these reasons, we manage many of our patients with active IIH without acetazolamide. The maximum dose is up to 2 g/daily; in our experience, up to 1 g daily is adequate, depending on body weight. If we do prescribe acetazolamide, we use the modified release preparation to reduce side effects.

Managing venous stenoses

Many patients with pseudotumour cerebri have venous sinus stenosis (narrowing), particularly of the transverse sinuses, reflecting elevated intracranial pressure.¹⁶

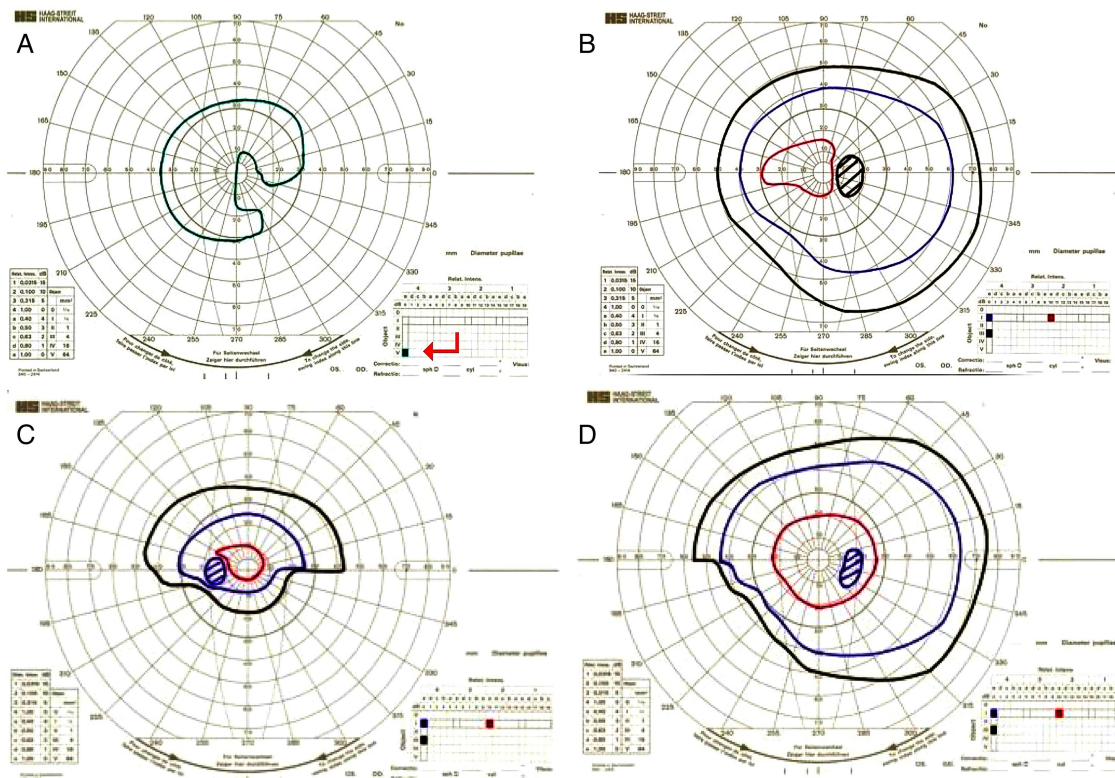


Figure 9 Case 2—Urgent CSF divergence surgery restored visual function. (A, B) Goldmann visual fields before and (C, D) after lumbar peritoneal shunt (left and right). (A) The left eye has an extensive visual field deficit and visual acuity of 1/60, the field is plotted (in green) only to the largest, brightest target called V4e (arrow). The patient was not able to perceive the smaller/ dimmer targets plotted in red, blue and black in figures 9B–D. (B) The right eye has an enlarged blind spot and reduced sensitivity of the visual field and visual acuity 6/18. (C and D) Left and right eye following the shunt show improved visual field and vision to 6/9 in both eyes.

Several research centres are now evaluating the therapeutic potential of stenting the transverse sinus in IIH.^{17–20} There is growing consensus that the stents do not treat the underlying cause of IIH. Reducing intracranial pressure by lumbar puncture can resolve the stenoses.²¹ Stenting the stenoses may, however, improve IIH by increasing CSF drainage at the arachnoid granulations, thereby lowering intracranial pressure and improving the signs and symptoms of IIH.^{17–20} Serious complication of the procedure (venous sinus perforation, stent migration, in-stent thrombosis, subdural haemorrhage and the development of recurrent stenoses immediately proximal to the stent) suggest the need for caution with this approach.^{17–19} We need larger long-term randomised clinical trials to evaluate this treatment before it can become routine clinical practice.²²

Managing the headache

The priority for patients with chronic IIH is usually the control of disabling headaches. IIH headache characteristics are very variable. Many do not have the classical features of IIH headache described by the International Headache Society²³ (progressive, daily, diffuse, non-pulsatile headache with aggravation by coughing or straining).²⁴ We note that pressure features, such as aggravation with Valsalva or cough and

severity worse in the morning (having been recumbent in the night) often do not occur, particularly as the condition becomes more chronic. The headaches typically alter during the course of the disease. In keeping with the literature, we find that headaches are often multifactorial, either due to raised intracranial pressure, low pressure, medication overuse headache, migraine or a combination of these.^{25–27} Migrainous features are particularly common (>70% of patients).²⁸ Our practice, particularly in those in whom headache is the principal complaint, is to evaluate the headache phenotype fully and to focus treatment towards the principal headache type. Those with chronic burnt-out disease—typically with stable vision and no or minimal papilloedema—often have the greatest headache disability. There is little evidence base to guide headache management in IIH. We look for, educate about, and treat the frequent situation of medication overuse in IIH. We successfully use topiramate—a migraine prophylactic agent with weak carbonic anhydrase inhibitor activity and an appetite suppressant (in about 10%),²⁹—to treat headache in IIH. Amitriptyline also helps to reduce the impact of migrainous headaches. A headache diary is very useful, not just to quantify the headache load, but also for the patient.

Managing IIH without papilloedema. These patients typically have chronic headaches, and in some their phenotype (obesity and female sex) or symptoms of pulsatile tinnitus prompt a lumbar puncture with pressure measurement. It is not clear if IIH without papilloedema is a distinct pathological entity^{30,31} and there is debate as to whether these patients represent just chronic daily headache with a coincidentally elevated intracranial pressure.³² Pressures in these patients tend to be significantly lower than in typical IIH.³³ Friedman *et al* has suggested that the diagnosis of IIH without papilloedema should only be made in those with a unilateral or bilateral sixth nerve palsy that also fulfil the criteria B-E in box 1. Alternatively, criteria B-E in association with at least three imaging findings suggesting raised intracranial pressure (empty sella, flattened posterior aspect of the globe, distended perioptic subarachnoid space \pm a tortuous optic nerve and transverse sinus stenosis).³ These criteria may be too stringent and lead to the under-identification of cases. Sixth nerve palsies are uncommon, even in cases with frank papilloedema. As these patients do not have (and do not seem to develop) papilloedema, they do not tend to develop visual loss, although they may develop functional visual loss.³³ Management focuses on treating the headache, and we use prophylactic and abortive agents appropriate for the headache phenotype.

Managing IIH in pregnancy

As IIH is common in women of childbearing age, there will inevitably be patients diagnosed with IIH who become pregnant. If the patient takes acetazolamide, we advise her to stop this on becoming pregnant, to minimise the risk of toxicity, particularly in the first trimester. However, in a series of 50 patients treated with acetazolamide during the first trimester, there were no reported adverse outcomes for the pregnancy or the baby.³⁴ We therefore occasionally consider using acetazolamide, particularly after the first trimester, following an informed discussion of the potential risks and benefits.³⁵ During pregnancy, we increase observations and begin communication with the obstetric team; we advise that the mother's birth plans are not changed simply due to their diagnosis of IIH. We recommend specialist dietary advice to guide on appropriate weight gain during pregnancy (eg, the Maternal Lighten Up program). The Institute of Medicine recommended 5–9 kg weight gain during the pregnancy (0.22 kg/week in the second and third trimester) in those with a starting Body Mass Index of ≥ 30 kg/m².³⁶ For the great majority, the IIH remains stable and they can have a normal vaginal delivery. Very occasionally, when there is compromised optic nerve function, we advise against a prolonged second stage of labour. Epidural and spinal anaesthetic during labour (even with a shunt in situ) can still go ahead.³⁷ A few patients present with IIH for the first time during the first trimester. If they have visual

compromise they may require temporising serial lumbar punctures, until they can undergo CSF diversion during their second trimester.

In the postpartum period, acetazolamide is probably safe for a breastfeeding baby. Only 0.06% of the dose of acetazolamide given to the mother is ingested by the child (less than 0.7% of the dose/kg body weight received by the mother); such a low dose is unlikely to harm the baby.³⁸

CONCLUSIONS

Patients presenting with papilloedema need careful evaluation and timely investigation. This is required to exclude all other causes of swollen optic nerves and raised intracranial pressure: IIH is a diagnosis of exclusion. Acute management depends on the immediate risk to vision. For most patients, this is a chronic condition associated with significant disability from headache. Disease-modifying therapy is weight loss. CSF shunting should be considered temporary. IIH requires a multidisciplinary approach involving ophthalmologists, neurologists and neurosurgeons. These patients are best managed in centres with expertise in IIH.

Practice points

- ▶ Distinguishing papilloedema from pseudopapilloedema is not always straightforward, and may require a senior ophthalmology opinion.
- ▶ Pseudotumour cerebri describes raised intracranial pressure and papilloedema in the absence of a space-occupying lesion and can be caused by several conditions (box 2). Idiopathic intracranial hypertension is a diagnosis of exclusion where NO cause can be found.
- ▶ A single lumbar puncture opening pressure reading can be misleading. Where the opening pressure is out of keeping with the clinical picture, the clinician should review the whole case.
- ▶ Monitoring of visual fields can be problematic in many patients who have functional overlay.
- ▶ Treat the patient. High-risk patients lose vision rapidly. Headaches may be multifactorial, and require specialist evaluation and treatment to reduce disability.

Contributors SM, KM, JB, AJ, TM, MB: article drafting, key concepts, revision and final approval of the manuscript. AS: article conception, design, drafting, revision and final approval of the manuscript.

Competing interests All authors declare that they have no proprietary or commercial interests in the subject matter. Dr Sinclair is funded by an NIHR Clinician Scientist Fellowship (NIHR-CS-011-028) and the Medical Research Council, UK (MR/K015184/1).

Provenance and peer review Commissioned; externally peer reviewed. This paper was reviewed by Brendan Davies, Birmingham, UK.

Open Access This is an Open Access article distributed in accordance with the Creative Commons Attribution Non Commercial (CC BY-NC 3.0) license, which permits others to distribute, remix, adapt, build upon this work non-commercially, and license their derivative works on different terms, provided the original work is properly cited and the use is non-commercial. See: <http://creativecommons.org/licenses/by-nc/3.0/>

REFERENCES

- Caballero B. The global epidemic of obesity: an overview. *Epidemiol Rev* 2007;29:1–5.
- Corbett JJ, Savino PJ, Thompson HS, *et al.* Visual loss in pseudotumor cerebri. Follow-up of 57 patients from five to 41 years and a profile of 14 patients with permanent severe visual loss. *Arch Neurol* 1982;39:461–74.
- Friedman DI, Liu GT, Digre KB. Revised diagnostic criteria for the pseudotumor cerebri syndrome in adults and children. *Neurology* 2013;81:1159–65.
- Brodsky MC, Vaphiades M. Magnetic resonance imaging in pseudotumor cerebri. *Ophthalmology* 1998;105:1686–93.
- Wright BL, Lai JT, Sinclair AJ. Cerebrospinal fluid and lumbar puncture: a practical review. *J Neurol* 2012;259:1530–45.
- Mollan SP, Ball AK, Sinclair AJ, *et al.* Idiopathic intracranial hypertension associated with iron deficiency anaemia: a lesson for management. *Eur Neurol* 2009;62:105–8.
- Whiteley W, Al-Shahi R, Warlow CP, *et al.* CSF opening pressure: reference interval and the effect of body mass index. *Neurology* 2006;67:1690–1.
- Glueck CJ, Aregawi D, Goldenberg N, *et al.* Idiopathic intracranial hypertension, polycystic-ovary syndrome, and thrombophilia. *J Lab Clin Med* 2005;145:72–82.
- Sinclair AJ, Kuruvath S, Sen D, *et al.* Is cerebrospinal fluid shunting in idiopathic intracranial hypertension worthwhile? A 10-year review. *Cephalalgia* 2011;31:1627–33.
- Sinclair A, Burdon M, Ball A, *et al.* Low energy diet and intracranial pressure in women with idiopathic intracranial hypertension: prospective cohort study. *BMJ* 2010;7:341.
- Newborg B. Pseudotumor cerebri treated by rice reduction diet. *Arch Intern Med* 1974;133:802–7.
- Li Z, Maglione M, Tu W, *et al.* Meta-analysis: pharmacologic treatment of obesity. *Ann Intern Med* 2005;142:532–46.
- Fridley J, Foroozan R, Sherman V, *et al.* Bariatric surgery for the treatment of idiopathic intracranial hypertension. *J Neurosurg* 2011;114:34–9.
- Jolly K, Lewis A, Beach J, *et al.* Comparison of range of commercial or primary care led weight reduction programmes with minimal intervention control for weight loss in obesity: lighten Up randomised controlled trial. *Bmj* 2011;343:d6500.
- Ball A, Howman A, Wheatley K, *et al.* A randomised controlled trial of treatment for idiopathic intracranial hypertension. *J Neurol* 2011;258:874–81.
- Farb RI, Vanek I, Scott JN, *et al.* Idiopathic intracranial hypertension: the prevalence and morphology of sinovenous stenosis. *Neurology* 2003;60:1418–24.
- Ahmed R, Friedman DI, Halmagyi GM. Stenting of the transverse sinuses in idiopathic intracranial hypertension. *J Neuroophthalmol* 2011;31:374–80. doi:10.1097/WNO.0b013e318237eb73 [published Online First: Epub Date].
- Ahmed RM, Wilkinson M, Parker GD, *et al.* Transverse sinus stenting for idiopathic intracranial hypertension: a review of 52 patients and of model predictions. *AJNR Am J Neuroradiol* 2011;32:1408–14.
- Albuquerque FC, Dashti SR, Hu YC, *et al.* Intracranial venous sinus stenting for benign intracranial hypertension: clinical indications, technique, and preliminary results. *World Neurosurg* 2011;75:648–52; discussion 592–5.
- Higgins JN, Cousins C,owler BK, *et al.* Idiopathic intracranial hypertension: 12 cases treated by venous sinus stenting. *J Neurol Neurosurg Psychiatry* 2003;74:1662–6.
- King JO, Mitchell PJ, Thomson KR, *et al.* Manometry combined with cervical puncture in idiopathic intracranial hypertension. *Neurology* 2002;58:26–30.
- Friedman DI. Cerebral venous pressure, intra-abdominal pressure, and dural venous sinus stenting in idiopathic intracranial hypertension. *J Neuroophthalmol* 2006;26:61–4.
- Evers S. The new IHS classification. Background and structure. *Schmerz* 2004;18:351–6.
- Ljubisavljevic S, Trajkovic J, Sternic N, *et al.* Idiopathic intracranial hypertension from the perspective of headache center. *Acta Neurol Belg* 2013;113:487–92.
- D'Amico D, Curone M, Ciasca P, *et al.* Headache prevalence and clinical features in patients with idiopathic intracranial hypertension (IIH). *Neurol Sci* 2013;34:147–49.
- Friedman DI, Rausch EA. Headache diagnoses in patients with treated idiopathic intracranial hypertension. *Neurology* 2002;58:1551–3.
- Gonzalez-Hernandez A, Fabre-Pi O, Diaz-Nicolas S, *et al.* [Headache in idiopathic intracranial hypertension]. *Rev Neurol* 2009;49:17–20.
- D'Amico D, Curone M, Faragò G, *et al.* Headache in patients with idiopathic intracranial hypertension: a pilot study to assess applicability of ICHD-2 diagnostic criteria. *Neurol Sci* 2012;33:189–91.
- Silberstein SD, Ben-Menachem E, Shank RP, *et al.* Topiramate monotherapy in epilepsy and migraine prevention. *Clin Ther* 2005;27:154–65.
- Marcelis J, Silberstein SD. Idiopathic intracranial hypertension without papilledema. *Arch Neurol* 1991;48:392–9.
- Wang SJ, Silberstein SD, Patterson S, *et al.* Idiopathic intracranial hypertension without papilledema: a case-control study in a headache center. *Neurology* 1998;51:245–9.
- Mathew NT, Ravishankar K, Sanin LC. Coexistence of migraine and idiopathic intracranial hypertension without papilledema. *Neurology* 1996;46:1226–30.
- Digre KB, Nakamoto BK, Warner JEA, *et al.* A Comparison of Idiopathic Intracranial Hypertension With and Without Papilledema. *Headache* 2009;49:185–93.
- Falardeau J, Lobb BM, Golden S, *et al.* The Use of Acetazolamide During Pregnancy in Intracranial Hypertension Patients. *J Neuroophthalmol* 2013;33:9–12.
- Lee AG, Pless M, Falardeau J, *et al.* The Use of Acetazolamide in Idiopathic Intracranial Hypertension During Pregnancy. *Am J Ophthalmol* 2005;139:855–59.
- Institute of M, National Research Council Committee to Reexamine IOMPWG. The National Academies Collection: Reports funded by National Institutes of Health. In: Rasmussen KM, Yaktine AL, eds. *Weight Gain During Pregnancy: Reexamining the Guidelines*. Washington, DC: National Academies Press (US) National Academy of Sciences, 2009; page 2.
- Karmanioliou I, Petropoulos G, Theodoraki K. Management of idiopathic intracranial hypertension in parturients: anesthetic considerations. *Can J Anesth/J Can Anesth* 2011;58:650–57.
- Soderman P, Hartvig P, Fagerlund C. Acetazolamide excretion into human breast milk. *Br J Clin Pharmacol* 1984;17:599–600.