



OPEN ACCESS

A 50-year-old with rapid neuropsychiatric deterioration and choreiform movements

Graham Andrew Mackay,¹ Stewart Campbell,² Ravi Jampana,³ Jonathan Cavanagh⁴

¹Department of Neurology, Queen Elizabeth University hospital, Glasgow, UK

²Department of Gastroenterology, Hairmyres hospital, East Kilbride, UK

³Department of Neuro-radiology, Queen Elizabeth University hospital, Glasgow, UK

⁴Mental Health and Wellbeing, Sackler Institute, Neurology block, Queen Elizabeth University hospital, Glasgow, UK

Correspondence to

Dr Graham Andrew Mackay, Department of Neurology, Queen Elizabeth University hospital, 1345 Govan road, Glasgow G51 4TF, UK; grahammackay@nhs.net

Accepted 07 December 2016

A 50-year-old man presented acutely to the hospital with behavioural disturbance, choreiform movements and profound nihilistic delusions. He reported recent drug and alcohol abuse, and also apparent involvement in several recent criminal activities, for which he felt he should be punished. He arrived alone at the hospital after a concerned neighbour had called an ambulance. His initial level of agitation prevented formal cognitive testing. However, he was alert, verbally responsive and could obey commands. He was afebrile with normal observations and normal plasma glucose. Although his examination was challenging, the only abnormal neurological findings were bilateral choreiform upper limb movements.

However, he still lived independently and attended training courses. His agitation and disorientation had developed over the 24 hours before presentation. There was no family history of dementia or of involuntary movements.

Question 2

What is the differential diagnosis?

Question 3

What initial investigations would you plan?

Causes of cognitive impairment and chorea ([Box 1](#)).

Urine screening for illicit drugs was negative. The following were normal: blood film, renal function, serum calcium, thyroid function tests and serum C-reactive protein; serum antistreptolysin O titres were negative. Urinalysis was normal. MR scan of the brain, including diffusion-weighted and susceptibility sequences, showed only minor non-specific white matter abnormalities. Cerebral MR angiography was also normal.

Comments

Before lumbar puncture, he was noted to have a prolonged activated partial thromboplastin time but normal prothrombin time. This did not correct with vitamin K, prompting his medical team to look for the lupus anticoagulant and for serum antinuclear antibodies. His lumbar puncture showed 20×10^6 red cells/l (0) and 10×10^6 white cells/l (≤ 5) (lymphocytes) with normal cerebrospinal fluid (CSF) protein and glucose concentrations. Oligoclonal band testing was equivocal. His serum was positive for antinuclear antibody (1/640), anti-double-stranded

Question 1

What should you do now?

Comments

Obtaining a collateral history is essential in establishing baseline function in people presenting with neuropsychiatric disturbance. This can help us focus on the differential diagnoses and plan for investigation. It can also avoid repeating previous investigations.

The admitting team contacted his brother, his next of kin. The patient was an unemployed ex-builder. One year earlier, he had consulted a movement disorder doctor with a high-frequency tremor and brief involuntary movements. Investigations at this time included a normal MR scan of the brain and routine blood tests, including thyroid function tests and serum calcium. In the 2 months before admission, his family had noticed occasional repetitive conversation.



CrossMark

To cite: Mackay GA, Campbell S, Jampana R, et al. *Pract Neurol* 2016;**0**:1–4.

TEST YOURSELF

Box 1 Differential diagnosis for rapid cognitive decline and chorea

- ▶ Drug-induced chorea, such as cocaine, amphetamines, lithium, methylphenidate, benzodiazepines, neuroleptics)
- ▶ Basal ganglia lesion
 - Stroke (sub-thalamic nucleus)
 - Space occupying lesion
- ▶ Postinfective, such as herpes simplex virus, Sydenham's chorea, paediatric autoimmune neuropsychiatric disorders associated with streptococcal infections, AIDS
- ▶ Thyrotoxicosis
- ▶ Systemic lupus erythematosus/antiphospholipid syndrome
- ▶ Polycythaemia rubra vera
- ▶ Chorea gravidarum
- ▶ Autoimmune encephalitis (NMDAR)
- ▶ Variant Creutzfeldt-Jakob disease
- ▶ Inherited conditions
 - Huntington's disease
 - Wilson's disease
 - Neuroacanthocytosis, Macleod's syndrome
 - Neuroferritinopathy/pantothenate kinase-associated neurodegeneration
 - Kufs disease, corticobasal degeneration, dentatorubral-pallidoluysian atrophy, Lesch-Nyhan syndrome
 - Friedreich's ataxia
 - Mitochondrial disorders

DNA (ELISA) at 840.4 U/mL (<35) and positive anti-DNA immunophoresis. He had a prolonged activated partial thromboplastin time and positive testing for the lupus anticoagulant (Dilute Russell's viper venom time (DRVT)). He had positive anticardiolipin IgG 16.9 U/mL (normal <10), but normal IgM levels. His serum complement C3 levels were initially low at 0.71 g/l (normal >0.8), with normal C4 levels.

Question 4

What is the most likely diagnosis?

Question 5

How would you initially treat him?

Comments

We made the presumptive diagnosis of diffuse neuropsychiatric lupus. He was originally treated with 5 days of intravenous methylprednisolone, with clear initial improvement in his agitation and lessening of his involuntary movements. He scored 54/100 on the revised Addenbrooke's Cognitive Assessment (ACE-R). The rheumatology team started him on tapering oral corticosteroids, followed by intravenous cyclophosphamide 500 mg weekly for 6 weeks. He did not

improve and, if anything, deteriorated further with more intrusive depressive thoughts, worsening cognitive function and a return of the chorea. He began complaining of visual hallucinations of a dog in his room.

Question 6

How would you manage him now?

Question 7

Are there any other treatment options and how might you monitor their impact?

Comments

Given his emerging depressive psychotic symptoms, we arranged for psychiatric evaluation. He was treated with venlafaxine and then additionally quetiapine, with a gradual impact on his depressive symptoms and resolution of the hallucinations. At this stage, he had five plasma exchange treatments without clear effect. An hexamethylpropyleneamine oxime (HMPOA) single photon emission CT (SPECT) showed bilateral cortical hypoperfusion, most prominent over the left temporal lobe ([figure 1](#)). Given his static and severely impaired cognitive function, we started him on intravenous rituximab. He received four weekly doses of 600 mg, having been screened for relevant infections (HIV, hepatitis B and C, and tuberculosis). His cognitive function significantly improved, the ACE-R score rising to 80/100. Repeat HMPOA SPECT showed increased perfusion ([figure 1](#)). During this time, he also received low-molecular-weight heparin for 6 weeks, given the associated antiphospholipid antibodies although vascular imaging never showed evidence of thrombosis. He now takes hydroxychloroquine as maintenance immunosuppressive therapy along with the venlafaxine and quetiapine. He manages self-care, but 12 months after initial presentation he still cannot yet live independently, requiring some supervision. His depression has resolved and his personality has returned to normal.

DISCUSSION

Most neuropsychiatric lupus events occur at onset or within an year of onset (50%–60%).¹ The American College of Rheumatology criteria for classifying neuropsychiatric lupus is very broad and includes 19 potential neurological and psychiatric syndromes ([table 1](#)), including both central and peripheral syndromes.² The spectrum of events varies from headache, mood disorders and mild cognitive impairment to severe cases.³ Severe cognitive cases such as this comprise only 3%–9% of neuropsychiatric lupus.^{1 4}

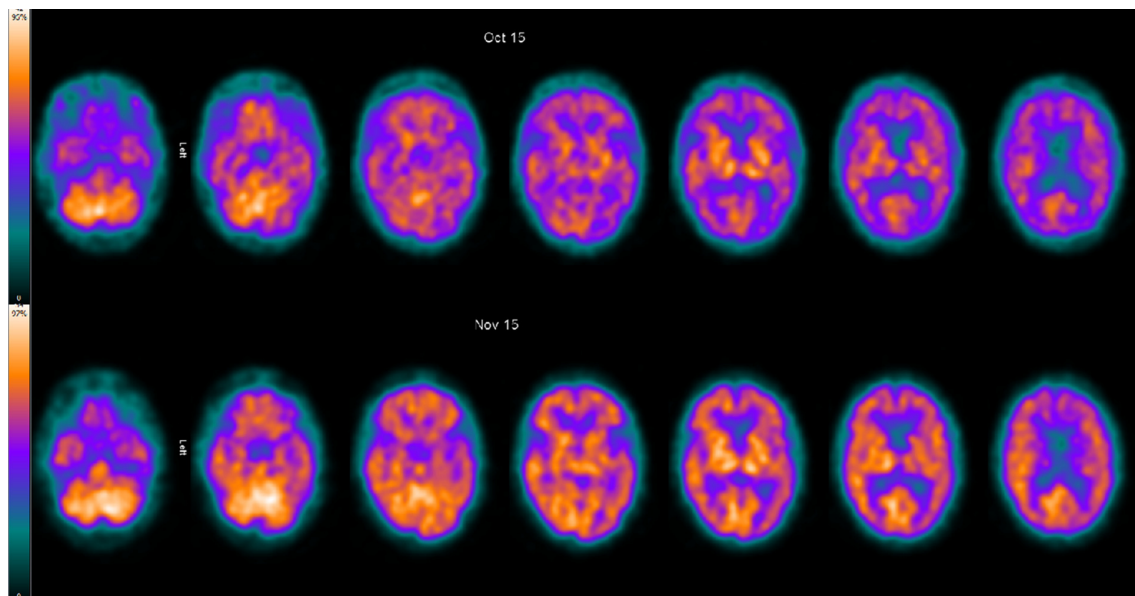


Figure 1 Cerebral perfusion single photon emission CT using intravenously injected ^{99m}Tc HMPAO. Axial projections. Pretreatment (top row) and post-treatment (bottom row) scans. As shown in the colour scale to the left, the brighter yellow the colour the greater the perfusion. Cortical perfusion is generally reduced on the pretreatment scan, but significantly improved after treatment.

Chorea is the most common movement disorder and is associated with antiphospholipid antibodies, but occurs in less than 4% of cases.^{1–3} Severe neuropsychiatric cases have either focal or diffuse presentations.^{5–7} The focal cases have ischaemic, thrombotic or demyelinating lesions. Our patient had a diffuse presentation, similar to several previously described cases. However, these diffuse cases were variably described as having severe neuropsychiatric lupus or acute confusional state presentations, making it difficult to compare the reported cases.

These diffuse cases are most likely immune mediated, possibly with several autoantibodies, including

antiribosomal-P, anti-DNA, antiphospholipid, NMDA NR2 and GABA-B antibodies, supporting this assertion.^{8,9}

Patients with suspected neuropsychiatric lupus should have an MR scan of brain¹⁰ to exclude several differential diagnoses, including demyelination, ischaemia or thrombosis. Over half of neuropsychiatric lupus cases have normal MR brain scans.^{5,8} Non-specific white matter abnormalities are common in systemic lupus erythematosus and in neuropsychiatric lupus cases, and are non-discriminatory.^{5,11} Serial MR brain scans in diffuse neuropsychiatric lupus cases may show rapidly progressive generalised brain atrophy.¹² Lumbar puncture is important to exclude central nervous system (CNS) infection; it can show an inflammatory response but can be normal. Some patients have positive CSF oligoclonal bands and other CSF immune biomarkers, such as anti-DNA antibodies, interleukin-6 and tumour necrosis factor alpha.⁹

Several studies have shown altered cerebral metabolism in neuropsychiatric lupus. Thus, SPECT scans may be diagnostically useful in patients with normal MRI, especially those with a diffuse cognitive presentation (where it is 75%–93% sensitive).^{1,9,13} SPECT scans may be used as a biomarker for the immediate response to immunotherapy,^{9,14} but do not help in subsequent monitoring or predicting further neuropsychiatric events.¹⁵

Patients with psychiatric symptoms should receive antidepressant and antipsychotic agents.¹ Electroconvulsive therapy was effective in three cases with severe psychosis.¹⁶ Patients with cognitive decline

Table 1 American College of Rheumatology Neuropsychiatric Systemic Lupus Erythematosus classification (1999)

| Central nervous system | Peripheral nervous system |
|-----------------------------|--|
| Aseptic meningitis | Acute inflammatory demyelinating polyradiculopathy |
| Cerebrovascular disease | Autonomic disorder |
| Demyelinating syndrome | Mononeuropathy (single/multiple) |
| Headache | Myasthenia gravis |
| Movement disorder (chorea)* | Cranial neuropathy |
| Myelopathy | Plexopathy |
| Seizure disorder* | Polyneuropathy |
| Acute confusional state* | |
| Anxiety disorder | |
| Cognitive dysfunction* | |
| Mood disorder* | |
| Psychosis* | |

*Presentations associated with diffuse neuropsychiatric lupus.

TEST YOURSELF

often respond to glucocorticoids and other immunosuppressants¹, although corticosteroids can aggravate the psychiatric symptoms. There is evidence for using cyclophosphamide and plasma exchange (sometimes synchronised) in refractory cases^{1 17} and for rituximab in severe refractory cases.^{9 13 14 18} Patients with either a long disease duration or with more than one of the American College of Rheumatology syndromes (table 1)¹³ have a poorer therapeutic prognosis.⁹ Although several CSF cytokine, chemokine and growth factors have been used as markers of the inflammatory process, a more specific biomarker would greatly improve diagnostic and therapeutic research into this rare condition.⁹

Competing interests None declared.

Provenance and peer review Not commissioned; externally reviewed. This paper was reviewed by Fady Joseph, Cardiff, UK.

Open Access This is an Open Access article distributed in accordance with the terms of the Creative Commons Attribution (CC BY 4.0) license, which permits others to distribute, remix, adapt and build upon this work, for commercial use, provided the original work is properly cited. See: <http://creativecommons.org/licenses/by/4.0/>

REFERENCES

- Bertsias GK, Ioannidis JI, Aringer M, *et al*. EULAR recommendations for the management of systemic lupus erythematosus with neuropsychiatric manifestations: report of a task force of the EULAR standing committee for clinical affairs. *Ann Rheum Dis* 2010;69:2074–82.
- The American College of Rheumatology nomenclature and case definitions for neuropsychiatric lupus syndromes. *Arthritis Rheum* 1999;42:599–608.
- Joseph FG, Scolding NJ. Neurolupus. *Pract Neurol* 2010;10:4–15.
- Brey RL, Holliday SL, Saklad AR, *et al*. Neuropsychiatric syndromes in lupus: prevalence using standardized definitions. *Neurology* 2002;58:1214–20.
- Arinuma Y, Kikuchi H, Wada T, *et al*. Brain MRI in patients with diffuse psychiatric/neuropsychological syndromes in systemic lupus erythematosus. *Lupus Sci Med* 2014;1:e000050.
- Postal M, Costallat LTL, Appenzeller S. Neuropsychiatric Manifestations in Systemic Lupus Erythematosus. *CNS Drugs* 2011;25:721–36.
- Aranow C, Diamond B, Mackay M. Glutamate receptor biology and its clinical significance in neuropsychiatric systemic lupus erythematosus. *Rheum Dis Clin North Am* 2010;36:187–201.
- Kivity S, Agmon-Levin N, Zandman-Goddard G, *et al*. Neuropsychiatric lupus: a mosaic of clinical presentations. *BMC Med* 2015;13:43.
- Ichinose K, Arima K, Umeda M, *et al*. Predictors of clinical outcomes in patients with neuropsychiatric systemic lupus erythematosus. *Cytokine* 2016;79:31–7.
- Scolding NJ, Joseph FG. The neuropathology and pathogenesis of systemic lupus erythematosus. *Neuropathol Appl Neurobiol* 2002;28:173–89.
- Zardi EM, Taccone A, Marigliano B, *et al*. Neuropsychiatric systemic lupus erythematosus: tools for the diagnosis. *Autoimmun Rev* 2014;13:831–9.
- Zivadnov R, Shucard JL, Hussein S, *et al*. Multimodal imaging in systemic lupus erythematosus patients with diffuse neuropsychiatric involvement. *Lupus* 2013;22:675–83.
- Castellino G, Padovan M, Bortoluzzi A, *et al*. Single photon emission computed tomography and magnetic resonance imaging evaluation in SLE patients with and without neuropsychiatric involvement. *Rheumatology* 2008;47:319–23.
- Narváez J, Ríos-Rodríguez V, de la Fuente D, *et al*. Rituximab therapy in refractory neuropsychiatric lupus: current clinical evidence. *Semin Arthritis Rheum* 2011;41:364–72.
- Castellino G, Bortoluzzi A, Padovan M, *et al*. Repeated brain conventional MRI and SPECT evaluation in systemic lupus erythematosus patients with and without neuropsychiatric involvement: a follow up study. *Lupus* 2011;20:1387–95.
- Tan LP, Tan LE. Electroconvulsive therapy for severe neuropsychiatric lupus with psychosis. *J ECT* 2013;29:243–6.
- Neuwelt CM. The role of plasmapheresis in the treatment of severe central nervous system neuropsychiatric systemic lupus erythematosus. *Ther Apher Dial* 2003;7:173–82.
- Cobo-Ibáñez T, Loza-Santamaría E, Pego-Reigosa JM, *et al*. Efficacy and safety of rituximab in the treatment of non-renal systemic lupus erythematosus: a systematic review. *Semin Arthritis Rheum* 2014;44:175–85.



A 50-year-old with rapid neuropsychiatric deterioration and choreiform movements

Graham Andrew Mackay, Stewart Campbell, Ravi Jampana and Jonathan Cavanagh

Pract Neurol published online January 24, 2017

Updated information and services can be found at:

<http://pn.bmj.com/content/early/2017/01/23/practneurol-2016-001481>

These include:

References

This article cites 18 articles, 4 of which you can access for free at: <http://pn.bmj.com/content/early/2017/01/23/practneurol-2016-001481#BIBL>

Open Access

This is an Open Access article distributed in accordance with the terms of the Creative Commons Attribution (CC BY 4.0) license, which permits others to distribute, remix, adapt and build upon this work, for commercial use, provided the original work is properly cited. See: <http://creativecommons.org/licenses/by/4.0/>

Email alerting service

Receive free email alerts when new articles cite this article. Sign up in the box at the top right corner of the online article.

Topic Collections

Articles on similar topics can be found in the following collections

[Open access](#) (29)

Notes

To request permissions go to:

<http://group.bmj.com/group/rights-licensing/permissions>

To order reprints go to:

<http://journals.bmj.com/cgi/reprintform>

To subscribe to BMJ go to:

<http://group.bmj.com/subscribe/>