Carphology by A Fo Ben

doi:10.1136/practneurol-2019-002222

A PAIN IN THE NECK

A packet of tramadol was identified wedged into a patient's gullet on oesophagogastroduodenoscopy (OGD). She had presented 17 days earlier with a sensation of something stuck in her throat, having taken her medication in the middle of the night. The object was not identified on chest and lateral neck X-rays, flexible nasoendoscopy, and the obstruction was misidentified as benign mucosal fold accumulation of fluid on a barium swallow. With persistent symptoms and clinical doggedness the foreign body was identified and removed on OGD, proving that one swallow does not make a summer (Figure 1). Medication adherence is a hot topic and innovative solutions need to be strongly considered. It is therefore with some dismay that A Fo Ben reads that this was purely accidental and indeed frightening for all concerned.

BMJ Case Rep. 2019;12(1).

Figure 1 Picture taken from oesophagogastroduodenoscopy; packet of tramadol tablets lodged in upper oesophagus.

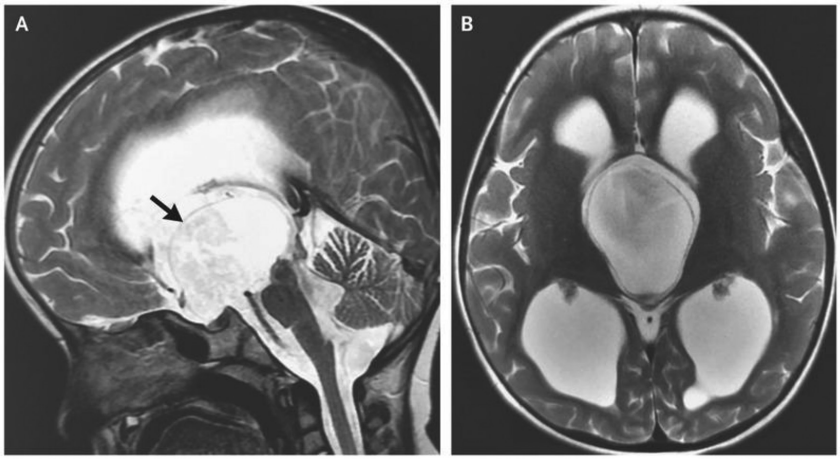

Figure 2 MR scan of brain shows a well-defined, thin-walled, suprasellar cystic lesion (A). The lesion caused obstruction at the foramen of Monro or at the third ventricle, with resulting ventriculomegaly (B).

NFL AND DEMENTIA

Medicine is full of TLAs (three-letter abbreviations); one man's SLE (systemic lupus erythematosus) is another man's stroke-like episode; NPC (Niemann-Pick type C) could also be nasopharyngeal carcinoma; and most commonly NAD (no abnormality detected) equates to 'not actually done'. And so, in the season of the Super Bowl, A Fo Ben asks the National Football League to stand aside for the new NfL in town: neurofilament light chain. Exploiting the Dominantly Inherited Alzheimer Network researchers looked at serial cerebrospinal fluid concentrations of NfL in 196 presymptomatic individuals. Not only can NfL levels identify people most likely to develop Alzheimer's dementia earlier, but the rate of change of serum NfL peaked in those who were converting to the symptomatic stage and was associated with cortical thinning on MRI.

Nat Med. 2019;25277–283. doi: 10.1038/s41591-018-0304-3.

NODDING OFF

The bobblehead (also known as the nodder, wobbler) is a type of collectible doll typically with an oversized head that crosses cultural boundaries. So spare a thought for the 5-year-old Indian written up in the *NEJM*. She has a suprasellar arachnoid cyst that caused continuous, rhythmic, anteroposterior head bobbing movements at a frequency of 2–3 Hz. The movements diminished in intensity when she was talking. 'Bobblehead-doll syndrome' is a rare paediatric movement disorder and the movements stop during sleep and may attenuate with volitional activity (Figure 2).

NEJM 2019;380(5):e5.

Funding The authors have not declared a specific grant for this research from any funding agency in the public, commercial or not-for-profit sectors.

Competing interests None declared.

Patient consent for publication Not required.

Provenance and peer review Commissioned; internally peer reviewed.

Pract Neurol: first published as 10.1136/practneurol-2019-002222 on 14 March 2019. Downloaded from http://pn.bmj.com/ on April 20, 2024 by guest. Protected by copyright.