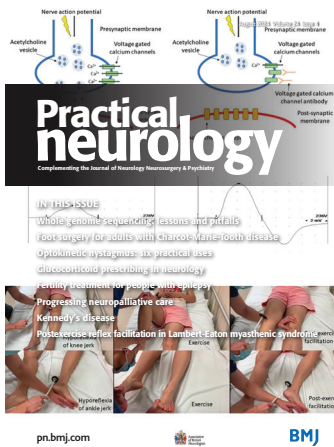

Cover image: Figure 3 (A) Pathophysiology of Lambert-Eaton myasthenic syndrome (LEMS): normal neuromuscular junction. (B) Pathophysiology of LEMS: LEMS neuromuscular junction. Figure 2 Compound muscle action potential (CMAP) of adductor digiti minimi pre-exercise (A1). CMAP of adductor digiti minimi postexercise showing incremental response of more than 100% improvement (A2). CMAP, compound muscle action potential. Figure 1 Post-exercise facilitation of knee jerk and ankle jerk. (see Poh M, *et al.* pages 339, 340).

## Highlights from this issue

**261** Editors' commentary  
P E M Smith, G N Fuller

## Editorial

**262** Progressing neuropalliative care  
E Husbands

## Reviews

**263** Lessons and pitfalls of whole genome sequencing  
C J Record, M M Reilly

**275** Foot surgery for adults with Charcot-Marie-Tooth disease  
M Laurá, J Barnett, J Benfield, G M Ramdharry, M J Welck

## How to do it

**285** Optokinetic nystagmus: six practical uses  
D E Hale, S Reich, D Gold

**289** Glucocorticoid prescribing in neurology  
A P Jones, M Debono, J Walsh, C Smith, L Hunt, F M McKeivitt

## What neurologists need to understand outside their own speciality

**296** Fertility treatment for people with epilepsy  
G Moores, K Liu, A Pikula, E Bui

## A difficult case

**302** Kennedy's disease  
H Devine, M Solomons, L Zampedri, M G Hanna, C Rinaldi, P Fratta, D Jayaseelan

**306** Encephalitis associated with anti-mGluR5 antibodies  
D A Pedrosa, J H F Ferreira, R Gleizer, R B Carra, R M de Carvalho, V Endmayr, R Hoftberger, L A Dutra

**310** Paroxysmal dysarthria-ataxia syndrome  
M Cauchi, J Abela, N Dingli, N Vella

**313** Shrinking lung syndrome mimicking diaphragmatic palsy in systemic lupus erythematosus  
S Mirg, A Das, A K Pandit, M C Sharma, A K Srivastava

**316** Carotid free-floating thrombus in patients with acute ischaemic stroke and active cancer  
R M Ventura, I Freire, J P Marto

## Neurological rarities

**320** Delayed onset post-traumatic wound botulism  
M Elrayes, S Al Bachari, R Macdonagh, A Peel, S Khurshid, J Hamzah, T Holzmann, A Chaouch, G Cummins, D McKee, A Richardson, C Kobylecki

**326** Dopa-responsive dystonia and paroxysmal dystonic attacks associated with *ATP1A3* gene variant  
M C Soares, J B Parmera, M E R Bezerra, R G Cury

## Image of the moment

**329** Spinal dural arteriovenous fistula  
A Berry-Noronha, N Ironside, W Collecutt, O Ameen, T Y Wu

**332** Simultaneous Horner's syndrome with anhidrosis and facial nerve palsy in internal carotid artery dissection  
T Herath, T H S Mbydeen, S Alagoda, M Saleh, L Naidu, S Wimalaratna


**335** Progressive multifocal leucoencephalopathy isolated to the brainstem and cerebellum  
D A Pedrosa, L Filipe de Souza Godoy, A Luiz Guimarães de Queiroz, C R Aparecida Vieira Stella, R B Thomaz

## Neurological sign


**338** Postexercise reflex facilitation in Lambert-Eaton myasthenic syndrome  
M Poh, Y C Ming, P C Yanni, G J Ng, Y H Ho, K Prasad, U Thiruganam

## Test yourself

**342** Young man with acute flaccid tetraparesis  
C R Dal Bo, F D De Carvalho, M B De Carvalho, R K Sakajiri, M d C Torquato, L Miniello, R d A Gleizer

 This article has been chosen by the Editor to be of special interest or importance and is freely available online.

 This article has been made freely available online under the BMJ Journals open access scheme. See <http://authors.bmj.com/open-access/>

 This journal is a member of and subscribes to the principles of the Committee on Publication Ethics

Member since 2008  
JMO0022  
[www.publicationethics.org](http://www.publicationethics.org)

 **recycle**  
When you have finished with this magazine please recycle it.

**A patient that changed my practice**

**345** End-of-life care  
A Nitkunan

**Book club**

**347** *The elements of eloquence* by  
Mark Forsyth  
C J S Nye

**ABN News**

**348** ABN news  
B Stanton, M McCourt

**Carphology**

**350** Carphology  
A F Ben