

## ME AND MY FATHER'S NEUROLOGICAL ILLNESS

# The tilted disc syndrome

**Anna Williams, (Adrian Williams and David Austen)**

Specialist Registrar in Neurology, Department of Clinical Neurosciences, Western General Hospital, Crewe Road, Edinburgh;

E-mail: acw@skull.dcn.ed.ac.uk

*Practical Neurology*, 2005, 5, 54–55

Ten years ago, when I was a medical student, my father developed a neurological problem. He went for his regular eye test, but also had his visual fields checked on the new Humphrey Field Analyser recently bought by the optometrists. Trouble followed. The test was repeated in greater detail, and he appeared to have a bitemporal superior quadrantanopia (Fig. 1a). He was referred to his general practitioner who referred him on to the local neurology department for further investigation. More trouble followed as my parents telephoned me (the only faintly medical person in the family) to ask for the potential causes, tests, treatments, operations and outlook.

My father was completely well, and had noticed no visual problem. My differential diagnosis then only consisted of one possibility – a pituitary tumour pressing on the optic chiasm. It had taken most of my second year at medical school to come to grips with neuroanatomy, but two weeks before the exam I had had a sudden enlightenment, and the visual pathway, at least, was crystalline in my mind.

I remember my parents picking me up at the beginning of the summer holidays and quizzing me, as we passed through Northumberland, about shrinking tumours with drugs, or neurosurgery done through the nose. Why do I remember that it occurred in Northumberland? Perhaps because this was my first attempt at trying to explain a medical condition, and to downplay possible unpleasantness to come.

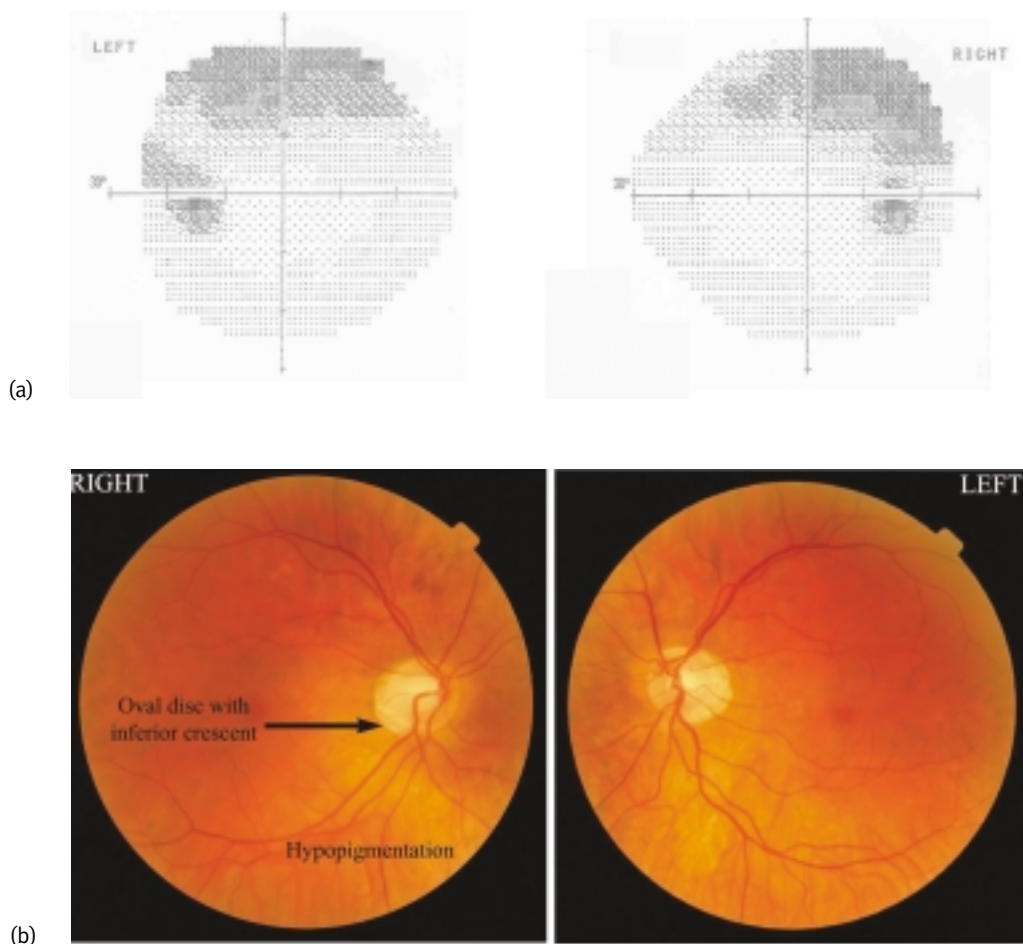
My father saw the professor of neurology. He then had a CT brain scan, probably because if

a tumour was pressing on the chiasm it should be big enough to see on a CT scan. Happily, this was normal, and thoughts of tumours receded. He was referred on to ophthalmology.

So, what was wrong with my father's eyes? He is myopic at around – 7.00 dioptres bilaterally, but sees fine with glasses, and his intraocular pressures have always been normal. He was followed up in ophthalmology for a number of years and his field tests improved to normal – the power of practice! We stopped worrying about it much. However, eventually, on one of his yearly reviews, he was seen by a visiting South African trainee who made the diagnosis. He had the 'tilted optic disc syndrome'.

Tilted disc syndrome had not reached the undergraduate curriculum, nor the big neurological tomes of Bradley or 'Brain', and still hasn't. It does merit a brief mention in Walsh and Hoyt's 10 volume *Clinical Neuro-Ophthalmology* and, after reading this, I found that my father is a classical case.

The tilted disc syndrome was first clearly described in 1944 (Rucker 1944). It is a benign optic disc anomaly where the optic nerve enters the eye at an angle other than a right angle. The disc looks oval and lopsided, usually elevated superiorly and depressed inferiorly. There is a crescent commonly inferior to the disc, and hypopigmentation in a wedge shaped area next to the defective portion of the disc. The blood vessels are often directed nasally before sweeping temporally, known as situs inversus. My father's retinal photographs in Fig. 1(b) show these features except situs inversus.



**Figure 1** (a) My father's visual field charts showing a field defect masquerading as a partial bitemporal upper quadrantanopia, except it crosses the midline – a clue to the diagnosis of tilted disc syndrome. Darker shading represents less vision. (b) My father's retinal photographs showing bilateral tilted disc syndrome. The discs look oval due to an inferior crescent bilaterally – the depressed side of the disc. The inferior-nasal retina is hypopigmented. The vessels emerge from the discs in the correct position.

The bitemporal superior field defect may be due to a nerve fibre defect in the inferior-nasal area of the disc. Alternatively, it may be a result of a refractive scotoma due to regional myopia confined to the inferonasal retina. However, the field defect does not respect the vertical midline, unlike chiasmal defects; repeating the field test with a – 4.00 dioptre lens can eliminate the defect

The tilted disc syndrome is commonly bilateral (80%) and has a prevalence of about 2% in the general population. However, about one-fifth of people with high myopia (> 5 dioptres) and astigmatism have tilted discs. Only about one-fifth of those with tilted discs have a field defect (Vongphanit *et al.* 2002). Yet this still makes tilted disc syndrome far more common than pituitary tumours/suprasellar lesions as the cause for such field defects.

So has my now extensive knowledge of tilted discs been useful in neurology? As a very new neurology trainee, I helped in the neuro-ophthalmology clinic and found myself taking a history from a young woman who had no symptoms, but an automated visual field test suggesting a bitemporal upper quadrantanopia. Her MR brain scan had been carried out that morning and was normal. I sensed, and achieved, a diagnostic coup – my second case of the tilted disc syndrome!

I look very much like my father and I have certainly inherited his myopia and astigmatism. I sometimes shut one eye and waggle my fingers in the superior temporal quadrants to check myself out, as there are recorded cases of an autosomal dominant tilted disc syndrome (Bottoni *et al.* 1990). All still seems well and despite my interest in genetics, I somehow think that I will be better off not investigating further.

#### ACKNOWLEDGEMENT

David Austen of Austen Optometrists, 46, Church Gate, Loughborough, Leicestershire, took the pictures, provided the field charts and made the first referral to the General Practitioner.

#### REFERENCES

- Bottoni FG, Eggink CA, Cruysberg JR & Verbeek AM (1990) Dominant inherited tilted disc syndrome and lacquer cracks. *Eye*, **4**, 504–9.
- Rucker CW (1944) Bitemporal defects in the visual fields resulting from developmental anomalies of the optic discs. *Archives of Ophthalmology*, **32**, 56–9.
- Vongphanit J, Mitchell P & Wang JJ (2002) Population Prevalence of Tilted Optic Disks and the Relationship of This Sign to Refractive Error. *American Journal of Ophthalmology*, **133**, 679–85.