


Cerebral venous sinus thrombosis associated with COVID-19

Ameeka Thompson,¹ Catherine Morgan,^{2,3} Paul Smith,⁴ Christopher Jones,¹ Harriet Ball,^{2,3} Elizabeth J Coulthard,^{2,3} Ed Moran,¹ Konrad Szewczyk-Krolikowski,² Claire M Rice ^{2,3}

¹Department of Infectious Disease, North Bristol NHS Trust, Bristol, UK

²Department of Neurology, North Bristol NHS Trust, Bristol, UK

³Clinical Neurosciences, Translational Health Sciences, Bristol Medical School, University of Bristol, Bristol, UK

⁴Department of Neuroradiology, North Bristol NHS Trust, Bristol, UK

Correspondence to

Claire M Rice, Clinical Neurosciences, Level 1 Learning and Research Building, Southmead Hospital, Bristol BS10 5NB, UK; c.m.rice@bristol.ac.uk

Accepted 15 September 2020

Coronavirus disease of 2019 (COVID-19) is well known to increase the risk of developing venous thromboembolism; thus, patients with COVID-19 may present to neurologists with cerebral venous sinus thrombosis. We present a patient presenting acutely with delirium, who after initial negative viral testing, was diagnosed with cerebral venous sinus thrombosis in association with COVID-19.

CASE REPORT

A 50-year-old man presented with delirium. PCR nasopharyngeal swabs for the severe acute respiratory syndrome coronavirus 2 (SARS-CoV-2) were negative but we made a diagnosis of probable COVID-19 based on clinical and radiological features according to European Centre for Disease Control case definition criteria.¹ Fibrinogen was 3.8 g/L (1.8–5.4) and neutrophil:lymphocyte ratio 14.4; age ≥ 50 years and neutrophil:lymphocyte ratio ≥ 3.13 have been associated with severe disease.² D-dimer was not recorded acutely. A non-contrast CT scan of head and CSF analysis on admission were normal. We started enoxaparin 40 mg once daily subcutaneously as prophylaxis for venous thromboembolism and he did not need ventilator support.

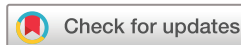Despite clinical improvement, he had persisting problems with executive dysfunction and dyspraxia. Repeat CT scan of head and CT venogram 1 week following admission showed dural venous sinus thrombosis involving the whole of the superior sagittal sinus, left transverse sinus and left sigmoid sinus down to the level of the jugular foramen. The vein of Labbé was also thrombosed and there was a small (7 × 8 mm) parenchymal haemorrhage within the left temporal lobe (figure 1). Shallow CSF density subdural collections were consistent with small hygromas (maximum depth 8 mm). The

radiological findings were in keeping with his cognitive profile although we noted that he did not have dysphasia. We fully anticoagulated him with intravenous heparin. After a further week, there was clinical and radiological improvement with re-canalisation of the vein of Labbé, partial re-canalisation of the left transverse sinus and superior sagittal sinus, reduced oedema in the left temporal lobe, but some acute haemorrhage within the slender hygromas. We briefly treated him with enoxaparin 1.5 mg/kg daily before switching to a direct oral anticoagulant on discharge from hospital. His anti-cardiolipin antibodies returned a positive result (278 IgG phospholipid units) but were not detected on interval testing (12 weeks). Beta-2 glycoprotein 1 IgM and IgG were normal.

DISCUSSION

Several studies have reported significantly increased rates of venous and arterial thromboses in patients with COVID-19 despite administration of standard prophylaxis, particularly among those with severe disease requiring intensive care support.^{3–5} The presence of venous thromboembolism has been associated with an increased risk of death.^{4, 5} Our centre noted 13 imaging-confirmed thromboembolic events in 12 of a total 352 (3.4%) consecutive patients requiring hospital admission for confirmed COVID-19 (March 9, 2020 to April 26, 2020). This compares with a reported incidence of 2% in H1N1 influenza.⁶ To date, however, cerebral venous sinus thrombosis has only rarely been reported in the context of COVID-19.^{7, 8}

The mechanism responsible for increased risk of thrombosis in COVID-19 is now beginning to be understood.^{9, 10} ACE 2 receptor facilitates cell entry of SARS-CoV-2,¹¹ and



© Author(s) (or their employer(s)) 2020. No commercial re-use. See rights and permissions. Published by BMJ.

To cite: Thompson A, Morgan C, Smith P, et al. *Pract Neurol* Epub ahead of print: [please include Day Month Year]. doi:10.1136/practneurol-2020-002678

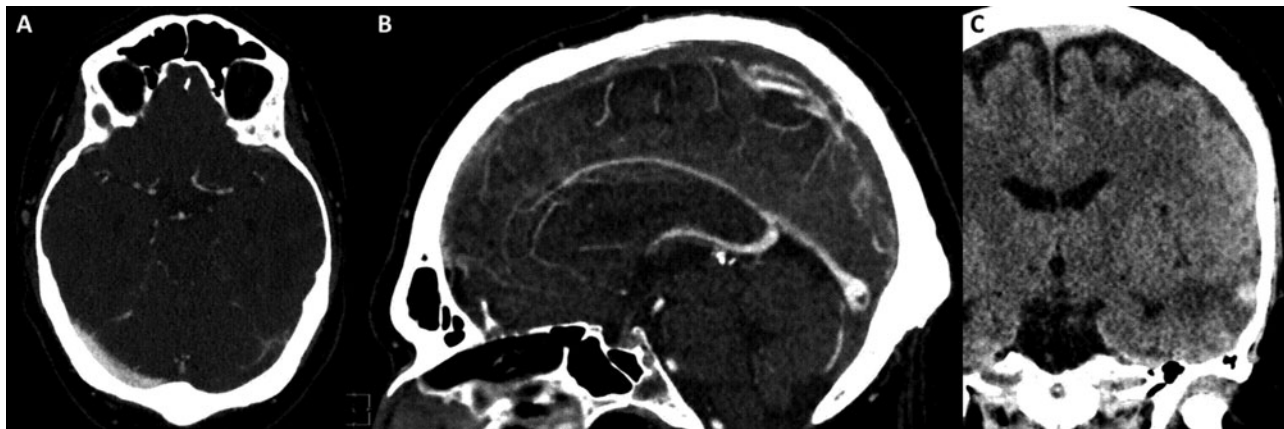


Figure 1 Cerebral venous sinus thrombosis with haemorrhagic infarct associated with COVID-19. (A) CT scan of head with contrast (1 mm axial) showing left transverse sinus thrombosis. (B) CT scan of head with contrast (sagittal) showing extensive superior sagittal sinus thrombosis. (C) CT scan of head (2 mm coronal minimum intensity projection) showing haemorrhagic infarct and surrounding oedema in the left temporal lobe.

is expressed on endothelial cells in multiple organ systems.¹² Viral infection of endothelial cells with associated endotheliitis¹³ and histological evidence of complement-mediated thrombotic microvascular injury have been demonstrated in COVID-19.¹⁴ Together with cytokine abnormalities,¹⁰ these contribute to vasoconstriction, ischaemia, inflammation and hyper-coagulopathy. Anti-phospholipid antibodies are common in severely ill patients and have previously been reported in the context of COVID-19. Their contribution to the development of coagulopathy remains uncertain and, as in this case, they may be transient.¹⁵ However, it has also been suggested that anti-cardiolipin antibodies may identify patients at greater risk of cerebral infarction.¹⁶

The optimal choice of anticoagulant and duration of treatment for cerebral venous sinus thrombosis is not known,¹⁷ and there are additional uncertainties in the thrombosis associated with COVID-19.¹⁸ We elected to use a direct oral anticoagulant before the anti-cardiolipin antibody result becoming available on the basis of ease of administration. Direct oral anticoagulants may be less effective than warfarin in the context of anti-phospholipid syndrome,¹⁹ although there is evidence to support their use in low-risk patients with anti-phospholipid syndrome and prior venous thromboembolism, that is who are not 'triple positive' with anti-cardiolipin antibody, anti-glycoprotein 1 antibody and lupus anticoagulant.²⁰ This patient has shown a positive response to treatment to date and we anticipate continuing anticoagulation for a minimum of 3 months,²¹ but will continue to review treatment.

This report highlights both the need to consider cerebral venous sinus thrombosis in patients presenting with headache, encephalopathy or focal neurological deficits.

Key points

- ▶ COVID-19 is commonly associated with coagulopathy.
- ▶ Cerebral venous sinus thrombosis associated with COVID-19 may present acutely to neurologists.
- ▶ The optimal choice of anticoagulant and duration of treatment for cerebral venous sinus thrombosis in the context of COVID-19 remains uncertain.

Twitter Elizabeth J Coulthard @LizCoulthard.

Acknowledgements We are grateful to the patient for permission to publish case report and to all members of the clinical team who were involved in patient care.

Contributors All authors contributed to data collection and analysis as well as drafting and review of the manuscript.

Funding The authors have not declared a specific grant for this research from any funding agency in the public, commercial or not-for-profit sectors.

Competing interests None declared.

Patient consent for publication Consent obtained directly from patient(s).

Ethics approval Patient consent has been provided for publication of case report.

Provenance and peer review Not commissioned. Externally peer reviewed by David Werring, London, UK.

Data availability statement All data relevant to the study are included in the article.

This article is made freely available for use in accordance with BMJ's website terms and conditions for the duration of the COVID-19 pandemic or until otherwise determined by BMJ. You may use, download and print the article for any lawful, non-commercial purpose (including text and data mining) provided that all copyright notices and trade marks are retained.

ORCID iD

Claire M Rice <http://orcid.org/0000-0002-9851-4426>

REFERENCES

- 1 Case definition for coronavirus disease 2019 (COVID-19) as of 29 May 2020: European centre for disease prevention and control (ECDC). 2020. <https://www.ecdc.europa.eu/en/COVID-19/surveillance/case-definition>
- 2 Liu J, Liu Y, Xiang P, *et al.* Neutrophil-to-lymphocyte ratio predicts critical illness patients with 2019 coronavirus disease in the early stage. *J Transl Med* 2020;18:206.
- 3 Lodigiani C, Iapichino G, Carezno L, *et al.* Venous and arterial thromboembolic complications in COVID-19 patients admitted to an academic hospital in Milan, Italy. *Thromb Res* 2020;191:9–14.
- 4 Middeldorp S, Coppens M, van Haaps TF, *et al.* Incidence of venous thromboembolism in hospitalized patients with COVID-19. *J Thromb Haemost* 2020;18:1995–2002.
- 5 Klok FA, Kruijff M, van der Meer NJM, *et al.* Incidence of thrombotic complications in critically ill ICU patients with COVID-19. *Thromb Res* 2020.
- 6 Avnon LS, Munteanu D, Smoliakov A, *et al.* Thromboembolic events in patients with severe pandemic influenza A/H1N1. *Eur J Intern Med* 2015;26:596–8.
- 7 Hughes C, Nichols T, Pike M, *et al.* Cerebral venous sinus thrombosis as a presentation of COVID-19. *Eur J Case Rep Intern Med* 2020;7:001691.
- 8 Hemasian H, Ansari B. First case of COVID-19 presented with cerebral venous thrombosis: a rare and dreaded case. *Rev Neurol (Paris)* 2020;176:521–3.
- 9 Bikkeli B, Madhavan MV, Jimenez D, *et al.* COVID-19 and thrombotic or thromboembolic disease: implications for prevention, antithrombotic therapy, and follow-up. *J Am Coll Cardiol* 2020;75:2950–73.
- 10 Jose RJ, Manuel A. COVID-19 cytokine storm: the interplay between inflammation and coagulation. *Lancet Respir Med* 2020;8:e46–e47.
- 11 Hoffmann M, Kleine-Weber H, Schroeder S, *et al.* SARS-CoV-2 cell entry depends on ACE2 and TMPRSS2 and is blocked by a clinically proven protease inhibitor. *Cell* 2020;181:271–80e8.
- 12 Hamming I, Timens W, Bulthuis ML, *et al.* Tissue distribution of ACE2 protein, the functional receptor for SARS coronavirus. A first step in understanding SARS pathogenesis. *J Pathol* 2004;203:631–7.
- 13 Varga Z, Flammer AJ, Steiger P, *et al.* Endothelial cell infection and endotheliitis in COVID-19. *Lancet* 2020;395:1417–18.
- 14 Magro C, Mulvey JJ, Berlin D, *et al.* Complement associated microvascular injury and thrombosis in the pathogenesis of severe COVID-19 infection: a report of five cases. *Transl Res J Lab Clin Med* 2020.
- 15 Devreese KMJ, Linskens EA, Benoit D, *et al.* Antiphospholipid antibodies in patients with COVID-19: a relevant observation? *J Thromb Haemost* 2020;18:2191–201.
- 16 Xiao M, Zhang Y, Zhang S, *et al.* Brief report: anti-phospholipid antibodies in critically ill patients with coronavirus disease 2019 (COVID-19). *Arthritis Rheumatol* 2020.
- 17 Ferro JM, Bousser MG, Canhao P, *et al.* European stroke organization guideline for the diagnosis and treatment of cerebral venous thrombosis – endorsed by the European academy of neurology. *Eur Stroke J* 2017;2:195–221.
- 18 Costa A, Weinstein ES, Sahoo DR, *et al.* How to build the plane while flying: VTE/PE thromboprophylaxis clinical guidelines for COVID-19 patients. *Disaster Med Public Health Prep* 2020;1–15.
- 19 Pengo V, Denas G, Zoppellaro G, *et al.* Rivaroxaban vs warfarin in high-risk patients with antiphospholipid syndrome. *Blood* 2018;132:1365–71.
- 20 Elsebaie MAT, van Es N, Langston A, *et al.* Direct oral anticoagulants in patients with venous thromboembolism and thrombophilia: a systematic review and meta-analysis. *J Thromb Haemost* 2019;17:645–56.
- 21 Guidance on venous thromboembolic disease in patients with COVID-19: British Thoracic Society (BTS). 2020. <https://www.brit-thoracic.org.uk/document-library/quality-improvement/COVID-19/bts-guidance-on-venous-thromboembolic-disease-in-patients-with-COVID-19/>