

# Cerebrotendinous xanthomatosis revisited

Seyed Mohammad Baghbanian <sup>1</sup>, Mohammad Reza Mahdavi Amiri,<sup>2</sup> Hadi Majidi<sup>3</sup>

<sup>1</sup>Faculty of Medicine, Department of Neurology, Mazandaran University of Medical Sciences, Sari, Iran  
<sup>2</sup>Laboratory Sciences, Medical Genetics, School of Allied Medical Sciences, Thalassemia Research Center, Hemoglobinopathy Research Institute, Mazandaran University of Medical Sciences, Sari, Iran  
<sup>3</sup>Department of Radiology, Orthopedic Research Center, Faculty of Medicine, Mazandaran University of Medical Sciences, Sari, Iran

## Correspondence to

Dr Seyed Mohammad Baghbanian, Faculty of Medicine, Department of Neurology, Mazandaran University of Medical Sciences, Sari, Iran (the Islamic Republic of); mohammadbaghbanian@gmail.com

Accepted 20 February 2021

## ABSTRACT

Cerebrotendinous xanthomatosis is a rare autosomal recessive lipid storage syndrome defined clinically by the triad of progressive neurodegeneration, juvenile cataracts and tendon xanthomas in adults. It is treatable, and a prompt diagnosis can improve outcomes. We describe a patient with this condition who presented with progressive ataxia.

## THE CASE HISTORY

A 35-year-old woman gave a 4-year history of progressive imbalance that had intensified over the last year. Her parents were cousins but there was no family history of neurological disease. She was born by normal delivery, and her neurological development had been normal. There was no history of seizure, neonatal icterus or hospitalisation for infection or infantile diarrhoea. She had a progressive learning disorder from the age of 14 years and had not entered high school. She had undergone bilateral cataract surgery when aged 21. On examination, there were non-tender swellings on both Achilles tendons and on the metacarpophalangeal joint of the third finger (figure 1). She had bilateral pes cavus. Her Mini-Mental State Examination Score was 24 of 30. She had truncal ataxia, bilaterally abnormal broken pursuit eye movements and spastic paraparesis with hyperreflexia and bilaterally extensor plantar responses. The remaining neurological examination was normal.

Her lipid profile identified a total serum cholesterol of 246 mg/dL (<200), high-density cholesterol 56 mg/dL (high risk <35) and low-density cholesterol 158 mg/dL (<200). HIV and human T-lymphotropic virus 1 and paraneoplastic/auto-immune panel results were negative. Serum vitamin B12 and E concentrations were normal. MR scan of brain showed bilateral dentate T2 hyperintensity and

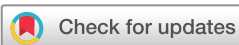T1 hypointensity with a comma sign on susceptibility-weighted imaging (SWI) (figure 2). DNA analysis with PCR identified a mutation in the *CYP27A1* gene, giving a preliminary diagnosis of cerebrotendinous xanthomatosis. There was a C.691C>T homozygote variant in the *CYP27A1* gene, a pathogenic mutant variant. Both parents had a heterozygote mutation of this gene.

## PATHOPHYSIOLOGY

A mutation in the *CYP27A1* gene (encoding sterol-27 hydroxylase) disrupts cholesterol's polarisation into bile acids, such as cholic acid and chenodeoxycholic acid.<sup>1</sup> This leads to a markedly high serum concentration of cholestanol as a bile acid intermediate, and, due to the hydrophobic characteristics of cholestanol, it deposits in lipophilic tissues such as the central nervous system, tendons and lens of the eye.<sup>1</sup> Cholestanol impairs calcium channel function, disrupting cell membrane stability and leading to cell death.<sup>2</sup>

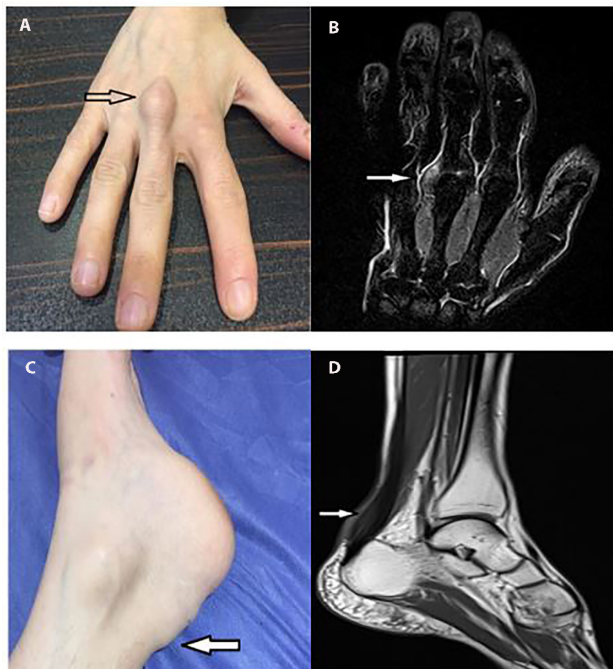
## CLINICAL FEATURES, DIAGNOSIS AND MANAGEMENT

Cerebrotendinous xanthomatosis presents neurologically as a combination of cerebellar and pyramidal signs with psychiatric disturbances.<sup>3</sup> The symptoms usually appear by the end of the first decade of life.<sup>1</sup> Not all patients have a positive family history.<sup>4</sup> Gastrointestinal symptoms such as diarrhoea are common due to impaired bile production. A juvenile cataract is an ophthalmic feature of this disease,<sup>1</sup> and this patient had undergone cataract surgery when aged 21. She also had deposition of large amounts of cholestanol and cholesterol in the tendons, especially the Achilles tendon, after the second decade of life; however, xanthomas in tendons are not specific to this disease.<sup>4</sup>



© Author(s) (or their employer(s)) 2021. No commercial re-use. See rights and permissions. Published by BMJ.

**To cite:** Baghbanian SM, Mahdavi Amiri MR, Majidi H. *Pract Neurol* Epub ahead of print: [please include Day Month Year]. doi:10.1136/practneurol-2020-002895

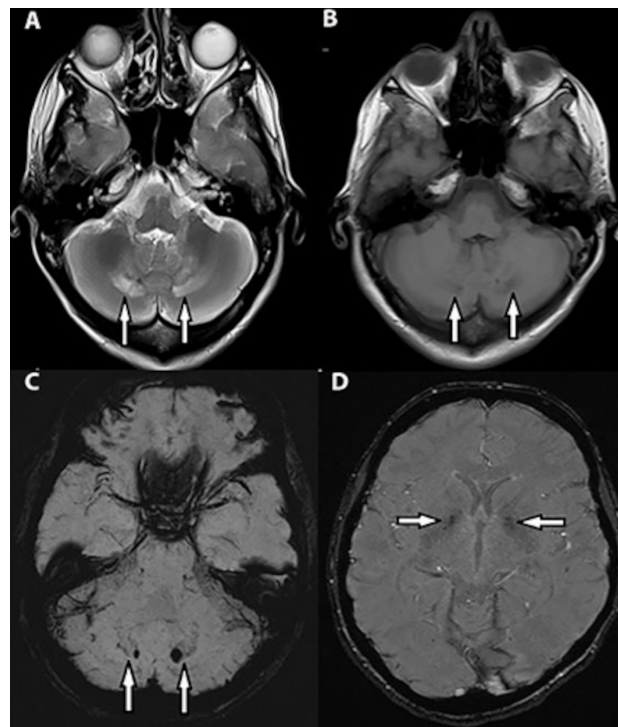


**Figure 1** Right hand swelling along the posterior aspect of the third metacarpal (A). MR scan of hand (T2-weighted) showing heterogeneous soft tissue mass-like lesion at the dorsal aspect of mid-portion of hand (adjacent to the head of the third metacarpal) wrapped around the third extensor tendon (B). Left ankle swelling in the region of Achilles tendon (C). MR scan of ankle (T2-weighted) showing hyperintense soft-tissue swelling in the posterior aspect of left Achilles tendon (D).

There are two main clinical neurological subgroups. The classic form has cerebellar–supratentorial symptoms and the spinal form presents with chronic myelopathy.<sup>5</sup> The current case had features from both these subgroups, with chronic cerebellar ataxia and spastic paraparesis. Cognitive problems are occasionally the early feature.

The hyperintensity of both dentate nuclei on MRI is a characteristic feature.<sup>6</sup> Calcification, small haemorrhage and the deposition of haemosiderin around the dentate nuclei,<sup>6</sup> which was filled by cholestanol, can lead to the comma sign,<sup>7</sup> is a characteristic feature of cerebrotendinous xanthomatosis in SWI.<sup>1</sup> Cerebral, cerebellar, brainstem atrophy and periventricular white matter lesions are also common on neuroimaging.<sup>6</sup> Early in the disease course, brain and spinal cord scans may be normal; the later the disease is diagnosed and the more severe the neurological disability, the more likely it is that the brain and spinal cord scans will be abnormal.<sup>4</sup> As a practical point, cognitive problems accompanying cataracts in a young person should prompt consideration of cerebrotendinous xanthomatosis.

The diagnosis of cerebrotendinous xanthomatosis is confirmed by high serum cholestanol concentrations and increased urinary excretion of bile acids.<sup>4</sup> However, DNA analysis with PCR, as used in our



**Figure 2** MR scan of brain (axial T2-weighted) showing hyperintensity (A) and T1-weighted showing hypointensity (B) of each dentate nucleus and deep cerebellar white matter. Susceptibility-weighted images show the comma sign in each dentate nucleus (C) and hypointensity of each posterior internal capsule (D).

patient, is now widely used to make the diagnosis. In this patient, we did not consider the differential diagnoses of dentate hyperintensity, including metronidazole intoxication and maple syrup urine disease, as there was no history of acute encephalopathy.<sup>1</sup> Cerebrotendinous xanthomatosis is one of few genetic diseases that can be treated, highlighting the need for early diagnosis. Chenodeoxycholic acid can halt progression and improve some neurological deficits. In a trial of chenodeoxycholic acid treatment in 17 patients with cerebrotendinous xanthomatosis, cognitive problems improved in 10 patients, and pyramidal and cerebellar symptoms improved significantly in 13 patients; the recovery lasted for up to a year.<sup>8</sup> It is not clear why the disease progresses in some patients despite treatment. The more severe the neurological manifestations are at

### Key points

- ▶ Cerebrotendinous xanthomatosis is a rare autosomal recessive lipid storage syndrome presenting with the triad of progressive neurodegeneration, juvenile cataracts, and tendon xanthomas.
- ▶ Chenodeoxycholic acid can halt its progression and improve some neurological deficits.

## Further reading list

- Nie S, Chen G, Cao X, et al. Cerebrotendinous xanthomatosis: a comprehensive review of pathogenesis, clinical manifestations, diagnosis, and management. *Orphanet J Rare Dis* 2014;**9**:179. doi:10.1186/s13023-014-0179-4. <http://www.ncbi.nlm.nih.gov/pubmed/25424010>.

the time of diagnosis the greater the progression of the disability despite treatment.<sup>4</sup> Our patient has not yet been treated.

**Twitter** Seyed Mohammad Baghbanian @smbaghbanian

**Contributors** SMB was the attending doctor of the patient and performed the neurological examination, prescribed medicines and decided the patient's management. MRMA served scientific advice about whole-exome sequencing and genetic consultation. HM performed scientific advice about MRI findings.

**Funding** The authors have not declared a specific grant for this research from any funding agency in the public, commercial or not-for-profit sectors.

**Competing interests** None declared.

**Patient consent for publication** Not required.

**Ethics approval** The Regional Ethics and Hospital Management Committee of Mazandaran University School of Medicine approved the study (IR.MAZUMS.REC.1399.307).

**Provenance and peer review** Not commissioned; externally peer reviewed by Marios Hadjivassiliou, Sheffield, UK.

## ORCID iD

Seyed Mohammad Baghbanian <http://orcid.org/0000-0002-8138-7504>

## REFERENCES

- 1 Verrips A, Hoefsloot LH, Steenberg GC, et al. Clinical and molecular genetic characteristics of patients with cerebrotendinous xanthomatosis. *Brain* 2000;**123**:908–19.
- 2 Seyama Y. Cholesterol metabolism, molecular pathology, and nutritional implications. *J Med Food* 2003;**6**:217–24.
- 3 Nie S, Chen G, Cao X, et al. Cerebrotendinous xanthomatosis: a comprehensive review of pathogenesis, clinical manifestations, diagnosis, and management. *Orphanet J Rare Dis* 2014;**9**:179.
- 4 Rafiq M, Sharrack N, Shaw PJ, et al. A neurological rarity not to be missed: cerebrotendinous xanthomatosis. *Pract Neurol* 2011;**11**:296–300.
- 5 Pilo-de-la-Fuente B, Jimenez-Escrig A, Lorenzo JR, et al. Cerebrotendinous xanthomatosis in Spain: clinical, prognostic, and genetic survey. *Eur J Neurol* 2011;**18**:1203–11.
- 6 Barkhof F, Verrips A, Wesseling P, et al. Cerebrotendinous xanthomatosis: the spectrum of imaging findings and the correlation with neuropathologic findings. *Radiology* 2000;**217**:869–76.
- 7 Parry AH, Wani AH, Bashir M, et al. Cerebrotendinous xanthomatosis - A case report. *Indian J Radiol Imaging* 2019;**29**:332.
- 8 Berginer VM, Salen G, Shefer S. Long-term treatment of cerebrotendinous xanthomatosis with chenodeoxycholic acid. *N Engl J Med* 1984;**311**:1649–52.