

Combined central and peripheral demyelination in two siblings, immune mediated or genetic?

K Moodley<sup>1</sup>, A.A Moodley<sup>1</sup>, S Efthymiou<sup>2</sup>, H Holden<sup>2</sup>, PLA Bill<sup>1</sup>, VB Patel<sup>1</sup>, S Rinaldi<sup>3</sup>

<sup>1</sup>Department of Neurology, University of KwaZulu-Natal, Durban, South Africa

<sup>2</sup>Department of Neuromuscular Disorders, UCL Queen Square Institute of Neurology, London, UK

<sup>3</sup>Nuffield Department of Clinical Neurosciences, University of Oxford, Oxford, UK

Correspondence to:

Dr Kaminie Moodley, Department of Neurology,  
University of KwaZulu-Natal, Durban, South Africa

[Kaminie@live.co.za](mailto:Kaminie@live.co.za)

Supplementary file: Table 1: Detailed nerve conduction studies of patient 1 and patient 2

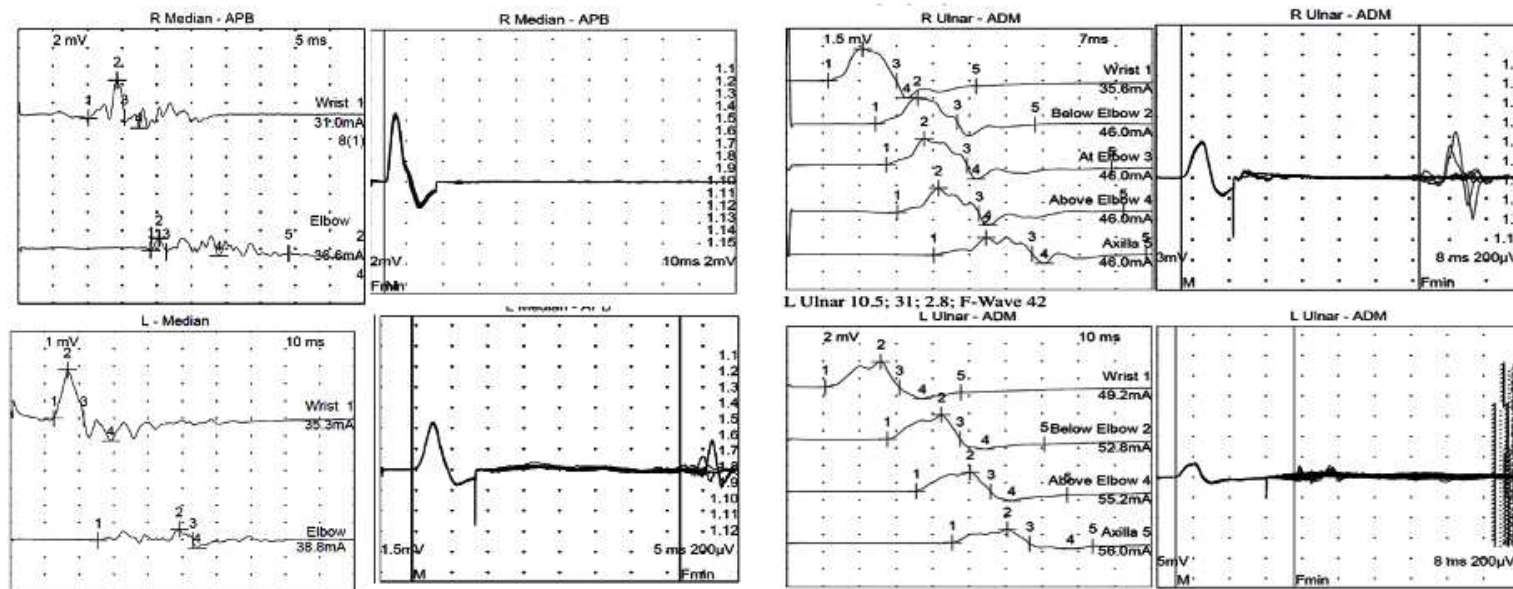
	Symptom duration to assessment	SNAPS	Motor studies							Inexcitable nerves	EMG	Neurophysiologist Report
				DML (ms)	Slow CV m/s	CMAP (mV)	CB	TD	F waves (m/s)			
Patient 1	1 month (2014)	Reduced UL SNAPS with prolonged latencies, absent LL sural SNAPS	R Median	9.8	28	3.8	++	+++	absent	All 4 LL nerves	No active denervation	Demyelinating
			L Median	11.3	26	3.4	++	+++	43			
			R Ulnar	8.1	29	3.1	+	+	56			
			L Ulnar	10.1	31	2.8	+	++	36			
	4 years (2018)	Absent SNAPS in all 4 limbs	R Median	8.9	20	1.5	+	+	58	All 4 LL nerves	Profuse denervation in TA and ADM, quadriceps, Lumbar paraspinals	Demyelinating with secondary axonal loss
			L Median	10.1	19	1.1			52			
			R Ulnar	7.8	22	1.8	+	+	50			
			L Ulnar	9.1	15	1.2			Absent			
Patient 2	2 weeks (2017)	Absent SNAPS in all 4 limbs	R Median	6.8	28	3.6	+	+	45	All 4 LL nerves	Denervation in TA, ADM, 1st DI, quadriceps and deltoid	Demyelinating with secondary axonal loss
			L Median	10.1	31	4.1	+		38			
			R Ulnar	11	21	2.9	++	++	Absent			
			L Ulnar	9.8	26	3.5	++	++	Absent			
	1 year (2018)	Absent in LL and reduced in UL	R median	6.2	31	3.3			42	All 4 LL nerves	Scant denervation in ADM, APB, TA	Demyelinating
			L Median	8.9	34	3.2	+	+	44			
			R Ulnar	9.8	34	3.6		+	42			
			L Ulnar	5.2	32	4.2			40			
5 years			Normal NCS in all 8 nerves									

DML=Distal motor latency, CV=Conduction velocity, SNAPS =sensory nerve action potential, CMAP=compound muscle action potential, TA=Tibialis Anterior, CB=conduction block, TD=temporal dispersion, NCS=nerve conduction studies

ADM= adductor digiti mini, 1<sup>st</sup> DI= first dorsal interossei, APB=Abductor Pollicis Brevis, LLN=lower limit of normal, LL=lower limb, UL=upper limb.

## Patient 1 at presentation

Median and ulnar nerve A) CMAP and B) F response recording from ABP and ADM respectively demonstrating temporal dispersion, conduction block and abnormal F responses.



A) Median CMAP

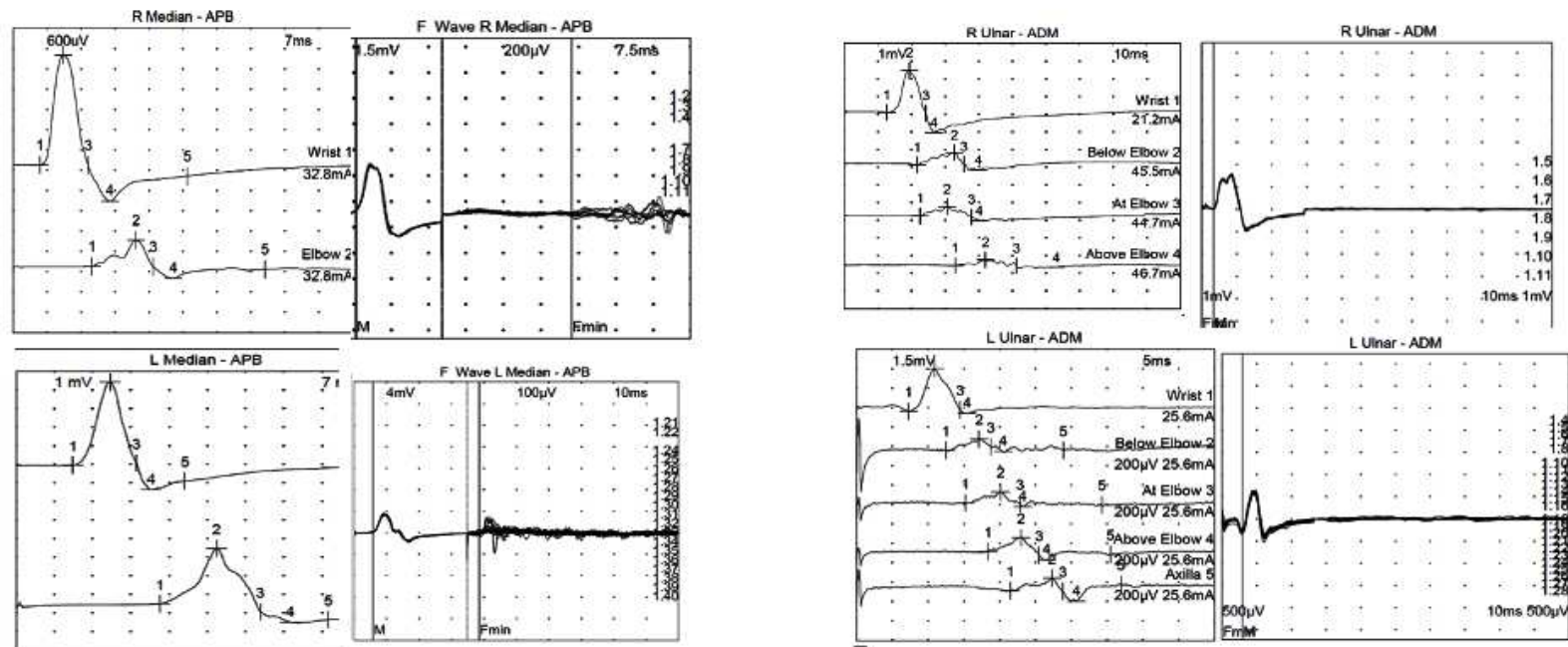
B) Median F wave

A) Ulnar CMAP

B) Ulnar F waves

## Patient 2 at presentation

Median and ulnar nerve A) CMAP and B) F response recording from ABP and ADM respectively demonstrating temporal dispersion, conduction block and abnormal F responses.



B) Median CMAP

B) Median F wave

A) Ulnar CMAP

B) Ulnar F waves

## Blood and CSF Investigations

Table 2A: Serological Blood investigations

	Connective Tissue Screen (ANA,Ro/SSA/La/SSB/ANCA)	SPEP	Paraneoplastic Antibodies	Aquaporin 4 & MOG antibodies	Paranodal Antibodies (NF 155, NF186, NF140, CasPr,CNTN1)	Ganglioside & glycolipids (Lactosylceramide)	Very Long chain fatty acids	Leucocyte aryl sulphatase A Enzyme activity
Patient 1	Negative	No paraprotein	Negative	Negative	Negative	Negative	No abnormality detected	121,4 units
Patient 2	ANA 1:160	No paraprotein	Negative	Negative	Negative	Negative	No abnormality detected	105,2 units

Full Blood count, Liver function tests ,urea and electrolytes ,calcium, magnesium and phosphate and serum angiotensin converting enzyme levels were normal in both patients

Table 2B: CSF Investigations

	HIV Status	CD4 cct cells/uL	Viral Load(copies/ml)	CSF Protein (g/L)	CSF OBs	CSF IgG index	CSF Neutrophils (cells/ul)	CSF Lymphocyte (cells/ul)	CSF Glucose (mmol/L)	Auramine stain, Gene expert Culture,VDRL,FTA abs, cryptococcal antigen, culture, HSV PCR,CMV PCR,HZ PCR, JCV PCR,	CSF Cytology
Patient 1	Negative	Not done	Not done	0.97	+ (T2 pattern)	0.81	0	0	3.5	Negative	No malignant cells
Patient 2	Positive	333	94712	1.28	+ (T2 pattern)	0.92	0	8	3.8	Negative	No malignant cells

VDRL=Veneral Disease Research Laboratory, TB=Tuberculosis, FTA abs= Fluorescent Treponemal Antibody absorption Test, HSV=Herpes Simplex Virus, CMV=cytomegalovirus, HZ=Herpes Zoster, JCV=John Cunningham virus, CSF=cerebrospinal fluid, T2 pattern OBs=oligoclonal IgG bands in the CSF but not in serum, suggesting intrathecal IgG synthesis. VL=viral load

Figure 1: OCT and fundal images of patient 1 demonstrating thickened retinal nerve fibre layer (OD: 293um and OS 191um) and swollen discs

